



Arthroscopic Bankart repair and subscapularis augmentation: an alternative technique treating anterior shoulder instability with bone loss

Marco Maiotti, MD^{a,*}, Raffaele Russo, MD^b, Antonio Zanini, MD^c,
Steffen Schröter, MD^d, Carlo Massoni, MD^a, Diana Bianchedi, MD^e

^aSports Traumatology Unit, San Giovanni-Addolorata Hospital, Rome, Italy

^bOrthopaedic and Traumatology Unit, Pellegrini Hospital, Naples, Italy

^cArthroscopy Unit, Carlo Poma Hospital, Mantua, Italy

^dBG Trauma Center Department of Traumatology, Eberhard Karls University, Tübingen, Germany

^eIsokinetic Group, Rome, Italy

Background: This study presents the preliminary results of a new arthroscopic technique consisting of the association of 2 procedures, capsulolabral repair and subscapularis augmentation tenodesis, in the treatment of traumatic anterior shoulder instability with both glenoid bone loss and a Hill-Sachs lesion.

Methods: Eighty-nine patients engaged in sports were enrolled in this retrospective case-series study with 2 to 5 years' follow-up. All patients underwent a computed tomography scan to assess the percentage of glenoid bone loss by the Pico method. A prior stabilization procedure had failed in 20 patients, who were then segregated into a different group. Visual analog scale (VAS), Rowe, and American Shoulder and Elbow Surgeons (ASES) scores were used to assess the results.

Results: Only 3 of 89 patients had a post-traumatic redislocation. The mean length of follow-up was 31.5 months (range, 25-60 months). The VAS, Rowe, and ASES scores showed significant improvements: The VAS score decreased from a mean of 3.1 to 0.5 ($P = .0157$), the Rowe score increased from 58.9 to 94.1 ($P = .0215$), and the ASES score increased from 68.5 to 95.5 ($P = .0197$). The mean deficit of external rotation was 6° with the arm at the side of the trunk, and the mean deficit was 3° with the arm in 90° of abduction.

Conclusions: The described procedure is a reproducible and effective technique used to restore joint stability in patients engaged in sports who have incurred anterior recurrent shoulder dislocation associated with glenoid bone loss (<25%) and a Hill-Sachs lesion.

This study was operational and by no means experimental. Therefore it did not require strict selection criteria or rigid actions or envisage violations. In addition, arthroscopic equipment and all devices used for arthroscopic repair and tendon fixation were already CE marked in Europe for orthopedic surgery for the period of the study. Accordingly, ethical approval was waived in light of the observational retrospective design. All patients

provided written informed consent for the index procedure, for phone or direct visit follow-up, and for the use of clinical data.

*Reprint requests: Marco Maiotti, MD, Sports Traumatology Unit, San Giovanni Addolorata Hospital, Via dell'Amba Aradam 9, I-00184 Rome, Italy.

E-mail address: m.maiotti@libero.it (M. Maiotti).

Level of evidence: Level IV, Case Series, Treatment Study.

© 2015 Journal of Shoulder and Elbow Surgery Board of Trustees.

Keywords: Traumatic shoulder instability; arthroscopic subscapularis augmentation; glenoid defect; Hill-Sachs lesion

Over the past few decades, arthroscopic anterior capsulolabral repair, which is focused on reconstructing labral and capsular ligamentous structures, has become the most popular method for the treatment of anterior shoulder instability, producing results that are nearly equivalent to open repair.^{1,3,4,12,48,60} To obtain the best results, this procedure must achieve an accurate reconstruction of the glenoid labrum with the correct number of anchors and physiological tension of the inferior glenohumeral ligament.^{16,42} Furthermore, glenohumeral bone integrity is mandatory.⁶

Burkhart and De Beer¹³ highlighted the role of bone defects in their failed cases. Importantly, the high failure rate of 67% was mainly because of significant bone defects such as anterior-inferior glenoid bone loss (GBL) or large engaging Hill-Sachs lesions.

In these cases, different techniques may be used as effective alternatives to anterior capsulolabral repair, ranging from the association of the Bankart repair and posterior remplissage^{5,11,59} to the open procedure^{1,8,14} or fully arthroscopic Bristow-Latarjet^{9,10,15,37,38} and bone graft procedures.^{40,46,52,55,58} However, the results of these procedures remain controversial.

The Hill-Sachs remplissage procedure presents its own rationale, whereas the potential for stable healing of the capsule and tendon on the humeral head and its role in the presence of anterior capsular deficiency and GBL has not yet been well defined.^{5,59} Moreover, the anatomy and function of the infraspinatus tendon are impaired.²⁷

Despite low recurrence rates and good clinical results, the Latarjet procedure is a nonanatomic reconstruction and may limit functionality and increase the rate of secondary osteoarthritis by up to 60%.^{1,30} Latarjet arthroscopic versions^{37,38,44} still represent highly demanding techniques with a significant number of intraoperative complications.^{30,31} Indications for bone graft procedures are not well defined, particularly in the presence of anterior capsulolabral insufficiency,^{25,32} and failure could occur because of graft reabsorption.²⁶ Moreover, to date, no study has shown which arthroscopic technique could be used in cases with bipolar bony defects (GBL and Hill-Sachs lesion) particularly in young active patients engaged in sports or after the failure of capsular and Bankart repairs.

In 1986 Johnson³⁵ described an arthroscopic technique that addressed recurrent shoulder dislocation in patients with “virtually nonexistent glenohumeral ligaments” using the articular portion of the subscapularis tendon; however,

this technique was abandoned because of potential complications related to the placement of metal staples for soft-tissue fixation adjacent to the level of the glenoid edge.^{22,33} More recently, Denard et al²⁴ and Chaudhury et al¹⁹ described 2 different procedures involving the subscapularis tendon to augment insufficient anterior capsulolabral tissue.

On the basis of Johnson’s concept, we developed a new surgical technique⁴¹ consisting of the combination of Bankart repair and arthroscopic subscapularis augmentation (ASA) with tenodesis of the upper third of the tendon (Fig. 1). Our purpose was to assess the short-term results of this technique to treat anterior shoulder instability in young active patients with a Hill-Sachs lesions, GBL (<25%), and insufficiency of the anterior capsulolabral unit in primary as well as in previous failed surgical procedures.

Methods

Study population

From January 2010 to April 2015, 250 patients were treated for traumatic anterior instability with arthroscopic Bankart repair and ASA by 4 surgeons in different shoulder units (M.M., A.Z., R.R., S.S.). Of these patients, 161 were excluded from this study because they could not fulfill the minimum 2-year follow-up.

Eighty-nine patients were available for follow-up ranging from 25 to 60 months (mean, 31.5 months). All examined patients were treated in the same sports unit from 2010 to 2013 by the same surgeon (M.M.), who is also the developer of the described technique. All patients reported engaging in sports activities (eg, contact and collision sports). The inclusion criteria were as follows: (1) patients with recurrent anterior dislocation (mean, 6 dislocations; range, 2-20 dislocations) and a positive apprehension test at 90° of abduction and (2) patients with a Hill-Sachs lesion (regardless of the size) and anterior GBL of less than 25% (mean, 10.8%; range, 8%-23%) as assessed by computed tomography (CT). The exclusion criteria were as follows: (1) GBL greater than 25%; (2) voluntary anterior, posterior, or multidirectional instability; (3) pre-existing glenohumeral osteoarthritis; and (4) overhead sports activities, assuming that a loss of external rotation might interfere with the sport-specific activities of throwing athletes.

Most of the patients were right hand dominant (70%), and there were 71 men and 18 women included in the study. The mean age was 29 years (minimum, 18 years; maximum, 38 years). Of the patients, 69 had undergone no previous procedures (group A). A prior arthroscopic capsulolabral repair had failed in the 20

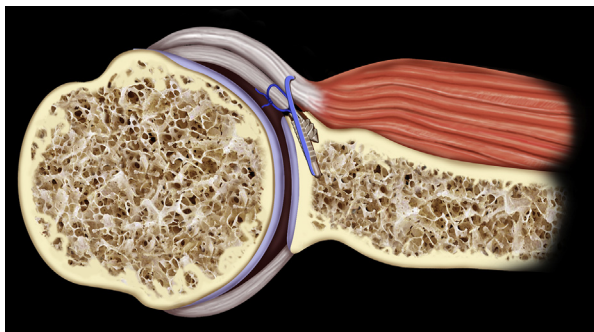


Figure 1 Arthroscopic subscapularis augmentation of Bankart repair.

patients comprising group B, with a minimum of 1 redislocation (range, 1-3 redislocations). In this group the recurrence had occurred during sports activities in 12 patients and after sporadic trauma during daily activities in 8 patients. The mean glenoid bone defect was 12% (range, 3%-21%). All of the patients were treated with absorbable anchors; 2 anchors were used in 12 patients, and 3 anchors were used in 8 patients.

Functional and radiologic assessments

Preoperative functional assessments of all patients were performed at the operative unit where the procedures were performed by 2 surgeons who used the Rowe score, visual analog scale (VAS) score for pain, and American Shoulder and Elbow Surgeons (ASES) score. One independent sports medicine practitioner (D.B.) conducted the postoperative ratings of functional results using consistent methods. The sports activity level was evaluated using the following rating system: grade I, no limitations in sports (100% of premorbidity level); grade II, moderate limitations in sports (>90% of premorbidity level); grade III, mild limitations in sports (>70% of premorbidity level); and grade IV, severe limitations in sports (<70% of premorbidity level).³⁶ These assessments could quantify apprehension, subluxation or recurrence of instability, functional level restrictions in activity, range of motion (ROM), and strength.

Preoperative imaging for all patients was performed using CT and the Pico surface area method⁷ to quantify the percentage of anteroinferior glenoid deficiency compared with the contralateral shoulder. A preoperative assessment of GBL was obtained using a 3-dimensional CT system (Optima CT660 64-slice multidetector CT; General Electric, Little Chalfont, UK) with multiplanar reconstructions of the glenoid neck and digital subtraction of the humeral head.

Magnetic resonance imaging (MRI) was effective in demonstrating labral modifications, and a Hill-Sachs lesion was documented in all cases. All patients underwent postoperative MRI examination to assess the position of the anchors and the absence of early osteochondral damage at 12 months postoperatively.

Surgical technique

The procedure was performed with the patient under an interscalene block in the lateral decubitus position; the arm was maintained at 40° of abduction and 15° of forward flexion with a balanced suspension of 5 to 10 lb (STaR Sleeve Traction System;

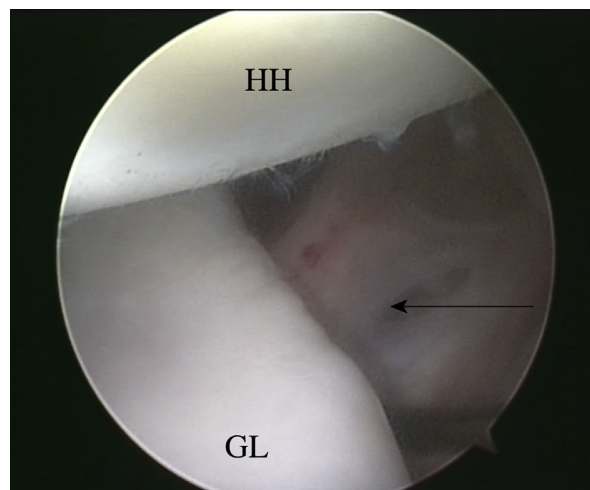


Figure 2 Capsulolabral deficiency and large anterior glenohumeral pouch (*arrow*), with absence of labrum. GL, glenoid; HH, humeral head.

Arthrex, Naples, FL, USA). Arthroscopy was performed using a 30° arthroscope and an arthroscopic pump to maintain a pressure of 60 mm Hg.

Standard anterior and posterior portals were used. A standard anterior portal was first localized using a spinal needle and subsequently established into the glenohumeral joint immediately over the superior border of the subscapularis tendon to obtain a 45° angle of approach to enable the use of suture-passing devices through the tendon tissue. An accessory portal was placed anterosuperiorly immediately above the standard portal. Two cannulas were used for the inferior and superior-anterior portals.

The anterior and posterior glenohumeral joint structures were inspected to assess any anteroinferior labral insufficiency (Fig. 2), superior labrum anterior-posterior (SLAP) lesions, anterior glenoid defects, and Hill-Sachs lesions and to confirm the anterior displacement of the humeral head with respect to the glenoid cavity. Arthroscopic tools from both anterior portals were used alternatively to prepare the glenoid neck, repair the labral tear, and augment the capsular insufficiency with the subscapularis tendon.

Suture anchor bone holes were placed on the anterior glenoid edge at the 3- or 5-o'clock position in a right shoulder or the 7- or 9-o'clock position in a left shoulder by first localizing the proper angle directly using a drill guide. An additional anchor bone hole was placed at the 1-o'clock position in a right shoulder or the 11-o'clock position in a left shoulder to repair a coexisting type II SLAP lesion.⁵¹

A lower capsular repair was performed with 2.9-mm nonabsorbable knotless polyetheretherketone suture anchors (PushLock; Arthrex) loaded with multistrand sutures (FiberWire; Arthrex). The middle upper third of the subscapularis tendon was penetrated at approximately 5 mm from its superior border using a suture-passing device (Fig. 3) loaded with tape (FiberTape; Arthrex).

Next, one of the free ends was obtained from the upper cannula using a suture retriever. Then, the same suture tape end was passed again in the lower cannula, forming a U-stitch with both ends of the tape. Use of a punch device was highly effective to assess the anchor bone hole direction and depth. At this point, both free ends of the tape were passed through the anchor's eyelet

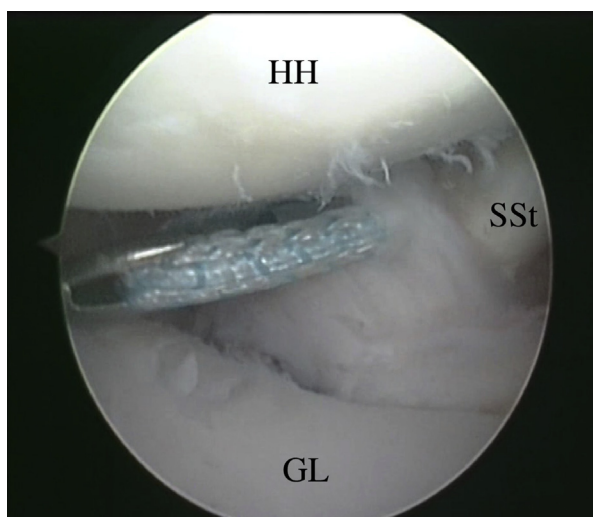


Figure 3 The subscapularis tendon (SSt) was penetrated using a suture-passing device loaded with multistrand tape. GL, glenoid; HH, humeral head.

and the anchor was pushed along the tape toward the bone hole (Fig. 4).

While the anchor was being inserted into the bone, the tape sutures were kept in traction in the parallel position and care was taken to maintain the patient's arm in neutral rotation to avoid excessive tension on the tissue repair. It is important for the surgeon to control the insertion of the anchor's eyelet and tape, maintaining the correct direction before impacting the anchor with a mallet.

The repair, including complete closure of the anterior pouch and centering of the humeral head in the glenoid cavity, was assessed by arthroscopic examination from the posterior and anterosuperior portals (Fig. 5). In patients with failure of a previous Bankart repair, anchor bone holes were drilled in the same position.

Statistical analysis

Baseline data obtained from the 89 participants who completed the study were analyzed using the analysis-of-variance and Fisher tests. The mean and 95% confidence interval of differences were evaluated using the analysis-of-variance test. Data were presented as the mean \pm standard deviation. The χ^2 test or Fisher test was used to compare our results with data obtained from previous studies. The level of significance was set at $P < .05$.

Arthroscopic findings

We divided our series into 2 groups on the basis of their primary pathology: group A included the findings from 69 patients who underwent primary Bankart repair and ASA, whereas group B included 20 patients who underwent reoperation after a previous surgical failure. In group A, the following associated lesions were observed among the 69 patients: 8 partial-thickness rotator cuff tears (11.5%), 8 type II SLAP lesions (11.6%), and 20

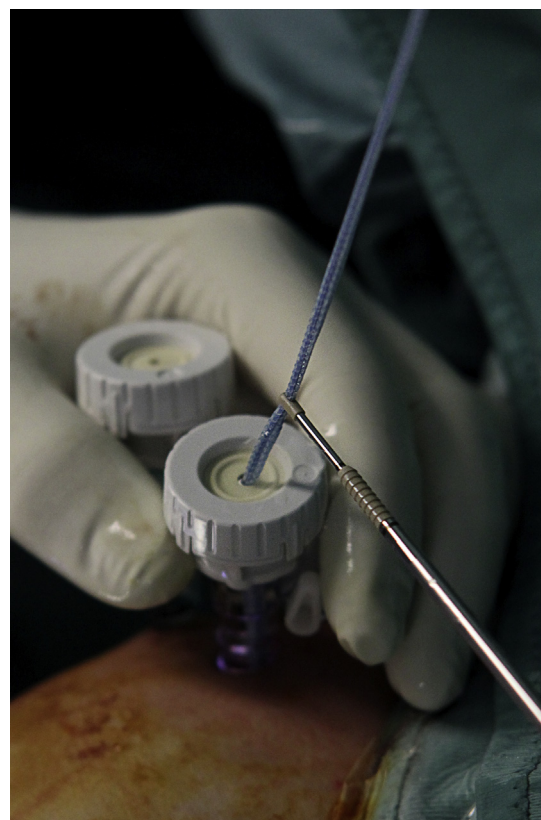


Figure 4 Both free ends of the tape were passed through the anchor's eyelet.

engaging Hill-Sachs lesions (22.5%). In 32 patients (46%), insufficiency of the anterior glenoid capsulolabral tissue was present; a loose body was found in 6 patients (8.7%). In 8 patients (11.5%) with partial-thickness rotator cuff tears, a debridement procedure was required; in patients with type II SLAP lesions, a concomitant labral repair was always performed using a third suture anchor. In 20 patients (22.5%), an engaging Hill-Sachs lesion was found. The operative findings in the group B patients were as follows: 2 cases of loose bodies (10%), 20 cases of capsulolabral insufficiency (100%), and 8 engaging Hill-Sachs lesions (40%).

Postoperative protocol

After surgical repair, the shoulder was immobilized in a brace with the arm in 0° of abduction and internal rotation for 4 weeks. The rehabilitation program consisted of 4 phases. The first phase was initiated in the fifth week, using both shoulder passive ROM and active ROM exercises to increase joint mobility. In the second phase, at 6 to 8 weeks, the aim was recovery of full ROM (Fig. 6). The third phase, at 8 to 9 weeks, was focused on the recovery of strength and proprioceptive abilities. In the fourth phase, at 10 weeks, the resumption of sport-specific activities was permitted. Return to sports was allowed at 4 months (Fig. 7). The same protocol was used in all patients.

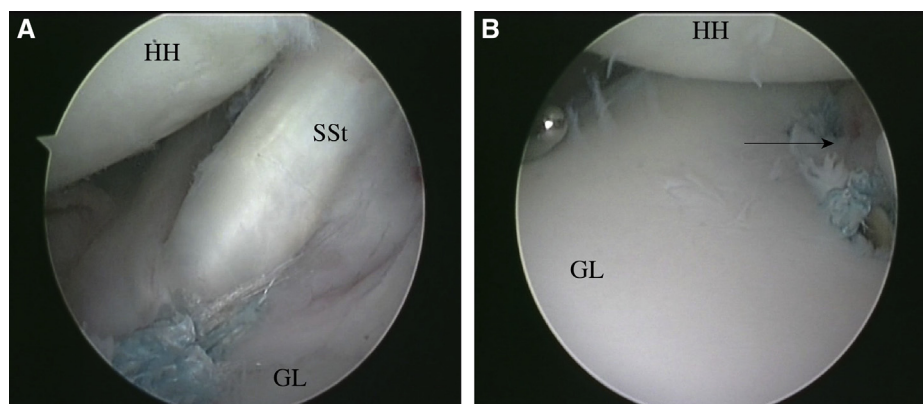


Figure 5 (A) Tenodesis of upper third of subscapularis tendon (SSt) (posterior view). (B) Anterosuperior view. The humeral head is centered in the glenoid cavity. The *arrow* indicates closure of the anterior pouch. GL, glenoid; HH, humeral head.

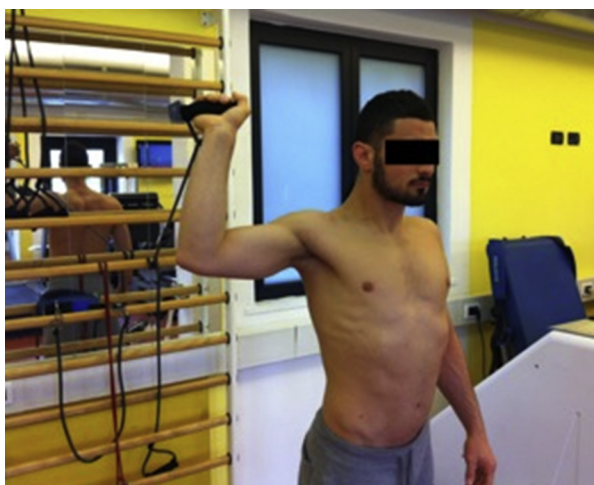


Figure 6 Absence of mobility restriction with arm in 90° of abduction.

Results

Eighty-nine patients were available for follow-up, which ranged from 2 to 5 years (mean, 31.5 months). All patients were rated using the VAS score, Rowe score, and ASES score. At the final follow-up, the mean scores of all patients were as follows: VAS score, 0.5 ± 0.8 ; Rowe score, 94.1 ± 6.7 ; and ASES score, 95.5 ± 5.2 (Table 1). A complaint of discomfort when placing the arm in external rotation and touching the back of the head was made by 4 patients (4.5%). A post-traumatic shoulder redislocation occurred in 3 patients (3.3%): in 2 of the patients, redislocation was due to a sports injury, whereas in 1 patient, redislocation occurred an accidental fall. One of these patients underwent a repeat ASA procedure. A second pilot hole was drilled, and the tenodesis was performed again using a 2.9-mm PushLock loaded with LabralTape (Arthrex). No complications related to the ASA procedure occurred. At the final follow-up, no significant differences were observed in shoulder forward flexion ($P = .258$),

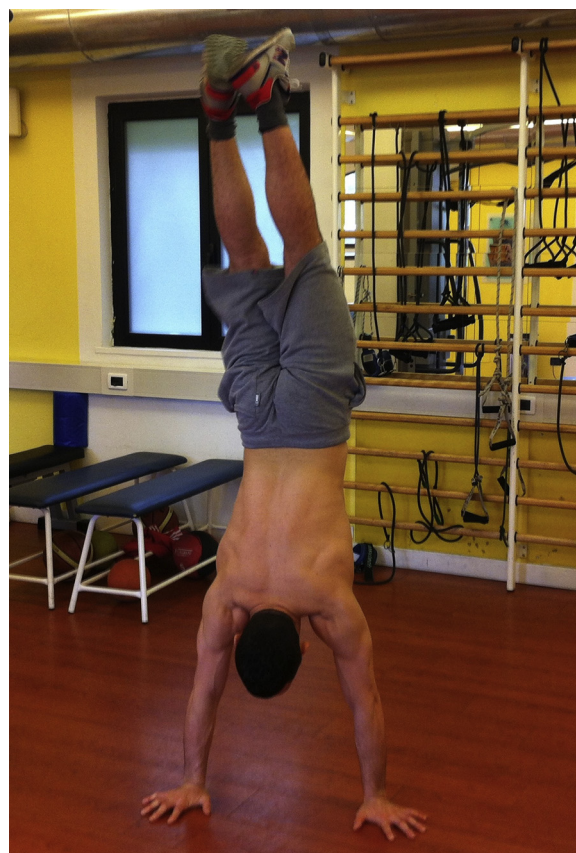

Figure 7 Complete recovery of shoulder stability.

extension ($P = .325$), and internal rotation ($P = .480$) compared with the normal contralateral side. In contrast, compared with the normal contralateral side, shoulder external rotation at the side ($P = .013$) and in abduction ($P = .0351$) significantly differed; moreover, the mean deficit of external rotation was 6° with the arm at the side of the trunk, and the mean deficit was 3° with the arm in 90° of abduction. All these functional and subjective results enabled all patients to return to full work activities. At the

Table I General functional outcomes

	Preoperative	Postoperative (FU)	Mean difference	P value	95% CI
VAS score	3.1 ± 1.3	0.5 ± 0.8	2.5	<i>P</i> = .0157	−2.79 to −2.30
Rowe score	58.9 ± 9.3	94.1 ± 6.7	35.2	<i>P</i> = .0215	32.97 to 37.36
ASES score	68.5 ± 9.5	95.5 ± 5.2	26.9	<i>P</i> = .0197	24.89 to 28.95

ASES, American Shoulder and Elbow Surgeons; CI, confidence interval; FU, follow-up; VAS, visual analog scale.

Data are presented as mean ± standard deviation.

final follow-up, no limitation in sports activities (grade I) was reported in 74 patients (83%), a moderate limitation of the premorbidity level (grade II) was reported in 12 patients (13%), and a mild limitation of sports activities (grade III) was reported in 3 patients (4%). No grade IV limitation was found. MRI evaluations at follow-up 12 months postoperatively showed good positioning of the anchors and no signs of early osteochondral damage (Fig. 8). We observed no significant difference between the final outcomes of group A patients (Table II) and the final outcomes of the patients with previous failed Bankart repairs (group B) (Table III).

Discussion

The purpose of our study was to assess the clinical results of ASA in combination with Bankart repair for the treatment of anterior shoulder instability with anterior GBL of less than 25% and a Hill-Sachs lesion in young active patients engaged in sports. The main significant finding was that the association of ASA with the classic Bankart repair yielded good clinical outcomes, good patient satisfaction scores, and functional improvement with a relatively low rate of recurrence. When assessed by the χ^2 test, our rate of recurrence (3.3%) was not significantly different (*P* < .05) from the data reported by Kim et al.³⁶ (*P* = .365, Mologne et al.⁴³ (*P* = .272), and Shibata et al.⁵⁰ (*P* = .413). However, these authors reported on patients who were not engaged in sports and who were affected by moderate GBL; their results showed that the failure rate ranged between 8.8% and 14%.

In the series reported by Lafosse and Boyle³⁷ (*P* = .125) and Walch and Boileau⁵⁷ (*P* = .301), the rate of recurrence was nearly zero. However, no statistical difference was found compared with our series.

The secondary purpose of this analysis was to evaluate the effectiveness of this new technique in patients with recurrence after arthroscopic Bankart repair (20 patients) and anterior GBL of less than 25%. Importantly, the good outcome of group B was unexpected because it is well known that it is difficult to perform an arthroscopic revision after a failed prior operation.^{17,30,50} The rate of recurrence of ASA (0%) for our revision surgery was significantly superior compared with other studies,^{2,17,23,24,28} in which the rate of recurrence has ranged from 16% to 30%.

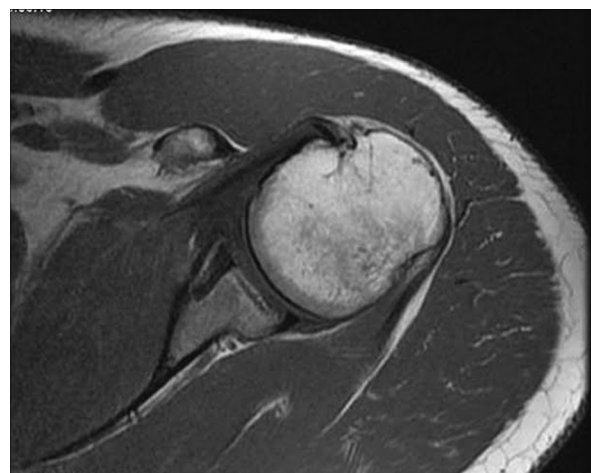


Figure 8 A postoperative magnetic resonance imaging scan (1.5-T; General Electric) shows good positioning of the anchors and absence of early osteochondral damage.

Many studies in the literature within the past 10 years have reported that the rate of recurrence after primary arthroscopic stabilization is highly variable,^{3,4,16,18,20,29} ranging from 0% up to 40% when a simple Bankart repair was performed and GBL was less than 25%. This resulted in a widespread recourse to techniques such as both the open^{45,57} and arthroscopic^{34,35} Bristow-Latarjet procedures, which were shown to systematically yield much lower recurrence rates. The overall failure rate in our series was 3.3% (3 of 89 patients): 3 patients in group A (which comprised 69 patients) and no patients in group B (which comprised 20 patients).

In our study, we aimed to probe whether arthroscopic “double soft-tissue” stabilization on the glenoid rim yielded good clinical functional results in an active young population with anterior GBL of less than 25% and, moreover, with engaging Hill-Sachs lesions, albeit without altering the anatomy of the coracoacromial arch. During the past century, the use of the subscapularis tendon as a mechanical barrier to prevent anterior instability was widely reported in the Putti-Platt procedure,^{21,39} which was subsequently modified by Symeonides.^{53,54} The use of the subscapularis tendon was also reported in the Magnuson-Stack procedure.⁴⁷ Long-term clinical reviews of the results of these open techniques have been controversial

Table II Functional outcomes in group A patients (n = 69)

	Preoperative	Postoperative (FU)	Mean difference	P value	95% CI
VAS score	3.2 ± 1.5	0.5 ± 1.2	2.7	P = .0175	−2.81 to −2.40
Rowe score	61.2 ± 8.4	95.5 ± 5.4	34.8	P = .0135	33.50 to 37.50
ASES score	69 ± 5.5	94.5 ± 3.5	25.5	P = .0193	25.61 to 28.52

ASES, American Shoulder and Elbow Surgeons; CI, confidence interval; FU, follow-up; VAS, visual analog scale. Data are presented as mean ± standard deviation.

Table III Functional outcomes in group B patients (n = 20)

	Preoperative	Postoperative (FU)	Mean difference	P value	95% CI
VAS score	3.15 ± 1.2	0.8 ± 1.3	2.4	P = .0235	−2.59 to −2.31
Rowe score	58.2 ± 12.2	96.4 ± 5.3	37.2	P = .0207	32.50 to 36.5
ASES score	67.6 ± 10.2	96 ± 7	28.4	P = .0147	24.5 to 27.95

ASES, American Shoulder and Elbow Surgeons; CI, confidence interval; FU, follow-up; VAS, visual analog scale. Data are presented as mean ± standard deviation.

because whereas these studies reported good results, even in patients practicing contact sports,^{21,61} joint stability was achieved to the detriment of external rotation; in this regard, because there is no agreement of results and no specific studies in the literature regarding throwing sports, as well as in light of the possibility of limitations of the cocking phase, which is specific to these types of sports activities, we believed that it was appropriate to exclude this category of sports. Furthermore, some authors proposed that this limitation of external rotation could cause secondary osteoarthritis.^{33,34,39} In our study, the loss of external rotation (6° with the arm at the side of the trunk and 3° with the arm in 90° of abduction) was significantly lower compared with the loss resulting from the open Putti-Platt procedure (ranging from 6° to 25°), and such a loss did not exceed the functional limitations of other types of techniques^{40,56,46,53,55,59} (ie, arthroscopic Bankart repair, Bankart repair plus remplissage, and open or arthroscopic bone-block transfers). The arthroscopic technique described by Johnson³⁵ was original; however, the use of metal staples for soft-tissue fixation adjacent to the level of the glenoid edge was criticized because of potential complications.³³ Recently, 2 techniques have been described in which the subscapularis tendon was used to treat anterior capsulolabral insufficiency. The first technique, described by Denard et al,²⁴ consisted of a subscapularis flap used to augment the Bankart repair, whereas the second technique, described by Chaudhury et al,¹⁹ consisted of a complete tenodesis of the tendon and its advancement and fixation to the medial border of the glenoid neck using a large number of anchors.

Another important observation in our study was the absence of early osteochondral damage after this type of surgery. The detection of secondary osteoarthritis after the open or arthroscopic treatment of instability is a highly

debated topic, and its true etiology remains unclear. According to some studies,^{29,32,34} when iatrogenic causes are excluded, osteoarthritis would appear to be secondary to the number of dislocations and the time elapsed between the first dislocation and the surgical repair. However, it has been reported that the use of all techniques, from open Bankart to open Latarjet procedures, may lead to high-grade osteoarthritis according to the classification of Samilson.^{1,30,34,39,49} Furthermore, the correlation between the Putti-Platt technique and early osteoarthritis remains controversial.^{21,61} We propose that an arthroscopic partial tenodesis of the upper part of the subscapularis tendon on the glenoid rim is not likely to cause early osteochondral damage, as shown by the MRI scans obtained 1 year postoperatively. To our knowledge, this is the first short-term but consecutive control-group study in which all patients were operated on by the same surgeon with an arthroscopic procedure using double soft-tissue stabilization with the upper third of the subscapularis tendon; moreover, no early or late complications were reported after this procedure. On the basis of the current knowledge regarding the GBL percentage and the Hill-Sachs lesion size necessary to determine an engaging head dislocation, these encouraging results prompted the consideration that this technique could have a definitive place in the treatment strategy for young recreational athletes and for individuals with previous failed surgical procedures, thereby avoiding the recourse to more complex procedures.

Limitations

There were a number of limitations in this study. The study was not a biomechanical study assessing the stabilizing effect of the procedure and the loss of shoulder motion compared with other techniques. The follow-up period was relatively brief, such that long-term outcomes, including the

incidence of late osteoarthritis, could not be studied. Thus it will be important to evaluate these patients at 10 years' follow-up. Furthermore, this study did not enable assessment of the quality of the tendon-to-bone tissue healing.

Conclusion

ASA is a safe procedure and provides good functional results for non-throwing athletes. It allows restoration of shoulder stability in patients with GBL of up to 25% and an engaging Hill-Sachs lesion, as well as capsular deficiency at the primary and secondary stabilization. Furthermore, ASA is effective in patients practicing contact sports, yielding a high rate of return to preinjury functional levels.

Disclaimer

Marco Maiotti is a senior consultant for Arthrex and was granted a research fund by Arthrex in 2015 but not for the purpose of this article.

Steffen Schröter was granted a research fund by Arthrex in 2015 but not for the purpose of this article.

The other authors, their immediate families, and any research foundations with which they are affiliated have not received any financial payments or other benefits from any commercial entity related to the subject of this article.

References

- Allain J, Goutallier D, Glorion C. Long-term results of the Latarjet procedure for the treatment of anterior instability of the shoulder. *J Bone Joint Surg Am* 1998;80:841-52.
- Arce G, Arcuri F, Ferro D, Pereira E. Is selective arthroscopic revision beneficial for treating recurrent anterior shoulder instability? *Clin Orthop Relat Res* 2012;470:965-71. <http://dx.doi.org/10.1007/s11999-011-2001-0>
- Arciero RA, Taylor DC, Snyder RJ, Uhorchak JM. Arthroscopic bioabsorbable tack stabilization of initial anterior shoulder dislocations: a preliminary report. *Arthroscopy* 1995;11:410-7.
- Bacilla P, Field LD, Savoie FH III. Arthroscopic Bankart repair in a high demand patient population. *Arthroscopy* 1997;13:51-60.
- Balg F, Boileau P. The instability severity index score. A simple preoperative score to select patients for arthroscopic or open shoulder stabilisation. *J Bone Joint Surg Br* 2007;89:1470-7. <http://dx.doi.org/10.1302/0301-620X.89B11.18962>
- Barak H, Mayo L, Biggs D. Outcomes of arthroscopic "remplissage": capsulotenodesis of the engaging large Hill-Sachs. *J Orthop Surg Res* 2011;6:29. <http://dx.doi.org/10.1186/1749-799X-6-29>
- Baudi P, Righi P, Bolognesi D, Rivetta S, Rossi Urtoler E, Guicciardi N, et al. How to identify and calculate glenoid bone deficit. *Chir Organi Mov* 2005;90:145-52.
- Bhatia S, Frank RM, Ghodadra NS, Hsu AR, Romeo AA, Bach BR Jr, et al. The outcomes and surgical techniques of the Latarjet procedure. *Arthroscopy* 2014;30:227-35. <http://dx.doi.org/10.1016/j.arthro.2013.10.013>
- Boileau P, Bicknell RT, El Fegoun AB, Chuinard C. Arthroscopic Bristow procedure for anterior instability in shoulder with a stretched or deficient capsule: the "belt and suspenders" operative technique and preliminary results. *Arthroscopy* 2007;23:593-601. <http://dx.doi.org/10.1016/j.arthro.2007.03.096>
- Boileau P, Mercier N, Roussanne Y, Thelù CE, Old J. Arthroscopic Bristow-Latarjet procedure: the development and early results of a safe and reproducible technique. *Arthroscopy* 2010;26:1434-50. <http://dx.doi.org/10.1016/j.arthro.2010.07.011>
- Boileau P, O'Shea K, Vargas P, Pinedo M, Old J, Zumstein M. Anatomical and functional results after arthroscopic Hill-Sachs remplissage. *J Bone Joint Surg Am* 2012;94:618-26. <http://dx.doi.org/10.2106/JBJS.K.00101>
- Boileau P, Villalba M, Hery JY, Balg F, Ahrens P, Neyton L. Risk factors for recurrence of shoulder instability after arthroscopic Bankart repair. *J Bone Joint Surg Am* 2006;88:1755-63. <http://dx.doi.org/10.2106/JBJS.E.00817>
- Burkhart SS, De Beer JF. Traumatic glenohumeral bone defects and their relationship to failure of arthroscopic Bankart repairs: significance of the inverted-pear glenoid and the humeral engaging Hill-Sachs-lesion. *Arthroscopy* 2000;16:677-94.
- Burkhart SS, De Beer JF, Barth JR, Cresswell T, Roberts C, Richards DP. Results of modified Latarjet reconstruction in patients with anteroinferior instability and significant bone loss. *Arthroscopy* 2007;23:1033-41. <http://dx.doi.org/10.1016/j.arthro.2007.08.009>
- Butt U, Charalambous CP. Arthroscopic coracoid transfer in the treatment of recurrent shoulder instability: a systematic review of early results. *Arthroscopy* 2013;29:774-9. <http://dx.doi.org/10.1016/j.arthro.2012.11.022>
- Carreira D, Mazzocca AD, Oryhon J, Brown FM, Hayden JK, Romeo AA. A prospective outcome evaluation of arthroscopic Bankart repairs: minimum 2-Year follow-up. *Am J Sports Med* 2006;34:771-7. <http://dx.doi.org/10.1177/0363546505283259>
- Castagna A, Garofalo R, Melito G, Markopoulos N, De Giorgi S. The role of arthroscopy in the revision of failed Latarjet procedures. *Musculoskelet Surg* 2010;94:S47-55. <http://dx.doi.org/10.1007/s12306-010-0060-0>
- Cerciello S, Edwards TB, Walch G. Chronic anterior glenohumeral instability in soccer players: results for a series of 28 shoulders treated with the Latarjet procedure. *J Orthop Traumatol* 2012;13:197-202. <http://dx.doi.org/10.1007/s10195-012-0201-3>
- Chaudhury S, Delos D, Dines JS, Altchek DW, Dodson CC, Newman AM, et al. Arthroscopic subscapularis Bankart technique as a salvage procedure for failed anterior shoulder stabilization. *HSS J* 2014;10:73-8. <http://dx.doi.org/10.1007/s11420-013-9370-8>
- Cole JB, L'Insalata J, Irrgang J, Warner JP. Comparison of arthroscopic and open anterior shoulder stabilization. *J Bone Joint Surg Am* 2000;82:1108-14.
- Collins K, Capito C, Cross M. The use of Putti-Platt procedure in the treatment of recurrent anterior dislocation. *Am J Sports Med* 1986;5:380-2.
- Coughlin L, Rubinovich M, Johansson J, White R, Greenspoon J. Arthroscopic staple capsulorrhaphy for anterior shoulder instability. *Am J Sports Med* 1992;20:253-6.
- Creighton RA, Romeo AA, Brown FM Jr, Hayden JK, Verma NN. Revision arthroscopic shoulder instability repair. *Arthroscopy* 2007;23:703-9. <http://dx.doi.org/10.1016/j.arthro.2007.01.021>
- Denard PJ, Narbona P, Lädermann A, Burkhart SS. Augmentation for capsulolabral deficiency using a split subscapularis tendon flap. *Arthroscopy* 2011;27:1135-41. <http://dx.doi.org/10.1016/j.arthro.2011.02.032>
- Dewing CB, Horan MP, Millett PJ. Two-year outcomes of open shoulder anterior capsular reconstruction for instability from severe

- capsular deficiency. *Arthroscopy* 2012;28:43-51. <http://dx.doi.org/10.1016/j.arthro.2011.07.002>
26. Di Giacomo G, Costantini A, de Gasperis N, De Vita A, Lin BK, Francone M, et al. Coracoid graft osteolysis after the Latarjet procedure for anteroinferior shoulder instability: a CT scan study of 26 patients. *J Shoulder Elbow Surg* 2011;20:989-95. <http://dx.doi.org/10.1016/j.jse.2010.11.016>
 27. Elkinson I, Giles W, Faber KJ, Boons HW, Ferreira LM, Johnson JA, et al. The effect of the remplissage procedure on shoulder stability and range of motion: an in vitro biomechanical assessment. *J Bone Joint Surg Am* 2012;94:1003-12. <http://dx.doi.org/10.2106/JBJS.J.01956>
 28. Friedman LG, Griesser MJ, Miniaci AA, Jones MH. Recurrent instability after revision anterior shoulder stabilization surgery. *Arthroscopy* 2014;30:372-81. <http://dx.doi.org/10.1016/j.arthro.2013.11.019>
 29. Green MR, Christensen KP. Arthroscopic versus open Bankart procedures: a comparison of early morbidity and complications. *Arthroscopy* 1993;9:371-4.
 30. Griesser MJ, Harris JD, McCoy BW, Hussain WM, Jones MH, Bishop JY, et al. Complications and re-operations after Bristow-Latarjet shoulder stabilization: a systematic review. *J Shoulder Elbow Surg* 2013;22:286-92. <http://dx.doi.org/10.1016/j.jse.2012.09.009>
 31. Griesser MJ, Harris JD, McCoy BW, Hussain WM, Jones MH, Bishop JY, et al. Glenoid fracture after Bristow-Latarjet shoulder stabilization: a case report and review of the literature. *J Shoulder Elbow Surg* 2013;22:e17-20. <http://dx.doi.org/10.1016/j.jse.2012.11.003>
 32. Habermeyer P, Gleyze P, Rickert M. Evolution of lesions of the labrum-ligament complex in post-traumatic anterior shoulder instability. *J Shoulder Elbow Surg* 1999;8:66-74.
 33. Hawkins RB. Arthroscopic stapling repair for shoulder instability: a retrospective study of 50 cases. *Arthroscopy* 1989;5:122-8.
 34. Hawkins RJ, Angelo RL. Glenohumeral osteoarthritis. A late complication of the Putti-Platt repair. *J Bone Joint Surg Am* 1990;72:1193-7.
 35. Johnson LL. *Arthroscopic surgery: Principle and practice*. St. Louis, MO: Mosby; 1986. p. 1420-4.
 36. Kim SJ, Kim SH, Park BK, Chun YM. Arthroscopic stabilization for recurrent shoulder instability with moderate glenoid bone defect in patients with moderate to low functional demand. *Arthroscopy* 2014;30:921-7. <http://dx.doi.org/10.1016/j.arthro.2014.03.023>
 37. Lafosse L, Boyle S. Arthroscopic Latarjet procedure. *J Shoulder Elbow Surg* 2010;19:2-12. <http://dx.doi.org/10.1016/j.ocl.2010.02.004>
 38. Lafosse L, Lejeune E, Bouchard A, Kakuda C, Gobeze R, Kochhar T. The arthroscopic Latarjet procedure for the treatment of anterior shoulder instability. *Arthroscopy* 2007;23:1242.e1-e5. <http://dx.doi.org/10.1016/j.arthro.2007.06.008>
 39. Leach RE, Corbett M, Schepsis A, Stochel J. Results of a modified Putti-Platt operation for recurrent shoulder dislocations and subluxations. *Clin Orthop Relat Res* 1982;164:20-5.
 40. Longo UG, Loppini M, Rizzello G, Ciuffreda M, Berton A, Maffulli N, et al. Remplissage, humeral osteochondral grafts, Weber osteotomy, and shoulder arthroplasty for the management of humeral bone defects in shoulder instability: systematic review and quantitative synthesis of the literature. *Arthroscopy* 2014;30:1650-66. <http://dx.doi.org/10.1016/j.arthro.2014.06.010>
 41. Maiotti M, Massoni C. Arthroscopic augmentation with subscapularis tendon in anterior shoulder instability with capsulolabral deficiency. *Arthrosc Tech* 2013;2:e303-10. <http://dx.doi.org/10.1016/j.eats.2013.04.005>
 42. Mead NC, Sweeney HJ. Bristow procedure. Spectator letter. Spectator Society. July 9, 1964. In: Rowe CR, editor. *The shoulder*. Philadelphia, PA: Churchill Livingstone; 1998. p. 222-3.
 43. Mologne TS, Provencher MT, Menzel KA, Vachon TA, Dewing CB. Arthroscopic stabilization in patients with an inverted pear glenoid: results in patients with bone loss of the anterior glenoid. *Am J Sports Med* 2007;35:1276-83. <http://dx.doi.org/10.1177/0363546507300262>
 44. Nourissat G, Nedellec G, O'Sullivan NA, Debet-Mejean A, Dumontier C, Sautet A, et al. Mini-open arthroscopically assisted Bristow-Latarjet procedure for the treatment of patients with anterior shoulder instability. A cadaver study. *Arthroscopy* 2006;22:1113-8. <http://dx.doi.org/10.1016/j.arthro.2006.06.016>
 45. Piasecki DP, Verma NN, Romeo AA, Levine VN, Bach BR, Provencher MT. Glenoid bone deficiency in recurrent anterior shoulder instability: diagnosis and management. *J Am Acad Orthop Surg* 2009;17:482-93.
 46. Provencher M, Ghodadra N, LeClere L, Solomon DJ, Romeo AA. Anatomic osteochondral glenoid reconstruction for recurrent glenohumeral instability with glenoid deficiency using a distal tibia allograft. *Arthroscopy* 2009;4:446-52. <http://dx.doi.org/10.1016/j.arthro.2008.10.017>
 47. Rodriguez Merchan EC, Ortega M. The Magnuson-Stack operation for recurrent anterior dislocation of the shoulder. *Int Orthop* 1994;18:356-8.
 48. Russo R, Togo F, Jannelli E. The surgical treatment of recurrent anterior dislocation of the shoulder. *Ital J Orthop Traumatol* 1990;16:183-9.
 49. Shah AA, Butler RB, Romanowski J, Karadagli D, Warner JJ. Short-term complications of the Latarjet procedure. *J Bone Joint Surg Am* 2012;94:495-501. <http://dx.doi.org/10.2106/JBJS.J.01830>
 50. Shibata H, Gotoh M, Mitsui Y, Kai Y, Nakamura H, Kanazawa T, et al. Risk factors for shoulder re-dislocation after arthroscopic Bankart repair. *J Orthop Surg Res* 2014;9:53. <http://dx.doi.org/10.1186/s13018-014-0053-z>
 51. Snyder SJ, Karzel RP, Del Pizzo W, Ferkel RD, Friedman MJ. SLAP lesions of the shoulder. *Arthroscopy* 1990;6:274-9.
 52. Steffen V, Hertel R. Rim reconstruction with autogenous iliac crest for anterior glenoid deficiency: forty-three instability cases followed for 5-19 years. *J Shoulder Elbow Surg* 2013;22:550-5. <http://dx.doi.org/10.1016/j.jse.2012.05.038>
 53. Symeonides PP. Reconsideration of the Putti-Platt procedure and its mode of action in recurrent traumatic anterior dislocation of the shoulder. *Clin Orthop Relat Res* 1989;246:8-15.
 54. Symeonides PP. The subscapularis muscle in the pathogenesis of recurrent anterior dislocation of the shoulder. *J Bone Joint Surg Br* 1972;54:476-8.
 55. Taverna E, Golanó P, Pascale V, Battistella F. An arthroscopic bone graft procedure for treating anterior-inferior glenohumeral instability. *Knee Surg Sports Traumatol Arthrosc* 2008;16:872-5. <http://dx.doi.org/10.1007/s00167-008-0541-y>
 56. Meulen PD, Weening AA, Derek FP, Van Deurzen DF, Van den Bekerom MP. The relevance of the Latarjet procedure for the management of humeral bone defects in anterior shoulder instability. *Arthroscopy* 2015;3:393-4. <http://dx.doi.org/10.1016/j.arthro.2015.01.001>
 57. Walch G, Boileau P. Latarjet-Bristow procedure for recurrent anterior instability. *Tech Shoulder Elbow Surg* 2000;1:256-61.
 58. Warner JJP, Gill TJ, O'Hollerhan JD, Pathare N, Millett PJ. Anatomical glenoid reconstruction for recurrent anterior glenohumeral instability with glenoid deficiency using an autogenous tricortical iliac crest bone graft. *Am J Sports Med* 2006;34:205-12. <http://dx.doi.org/10.1177/0363546505281798>
 59. Wolf EM, Arianjam A. Hill-Sachs remplissage, an arthroscopic solution for the engaging Hill-Sachs lesion: 2-to 10-year follow-up and incidence of recurrence. *J Shoulder Elbow Surg* 2014;23:814-20. <http://dx.doi.org/10.1016/j.jse.2013.09.009>
 60. Wolf EM, Wilk RM, Richmond JC. Arthroscopic Bankart repair using suture anchors. *Op Tech Orthop* 1991;1:184-91.
 61. Zaffagnini S, Marcacci M, Loreti I, Visani A, Vascellari A. Results of the original Putti-Platt procedure for shoulder instability. Review of Putti's scholar experience. *Knee Surg Sports Traumatol Arthrosc* 2000;8:314-9.