

The effect of the arthroscopic augmentation of the subscapularis tendon on shoulder instability and range of motion: A biomechanical study



S. Schröter^{a,*}, M. Krämer^b, B. Welke^b, C. Hurschler^b, R. Russo^d, M. Herbst^a, U. Stöckle^a, A. Ateschrang^a, M. Maiotti^c

^a Department of Traumatology and Reconstructive Surgery, Eberhard Karls University Tübingen, BG Trauma Center Tübingen, Germany

^b Laboratory for Biomechanics and Biomaterials, Department of Orthopaedics, Medical University Hannover, Hannover, Germany

^c Sports Medicine Unit, San Giovanni-Addolorata Hospital, Rome, Italy

^d Pellegrini Hospital Orthopaedic and Traumatology Unit, Naples, Italy

ARTICLE INFO

Article history:

Received 7 February 2016

Accepted 21 August 2016

Keywords:

A.S.A.

Arthroscopic subscapularis augmentation

Shoulder dislocation

Glenoid bone defect

Subscapularis elongation

ABSTRACT

Background: Anterior shoulder dislocation is common. The treatment of recurrence with glenoid bone defect is still considered controversial. A new arthroscopic subscapularis augmentation has recently been described that functions to decrease the anterior translation of the humeral head. The purpose of the presented study was to examine the biomechanical effect on glenohumeral joint motion and stability.

Methods: Eight fresh frozen cadaver shoulders were studied by use of a force guided industrial robot fitted with a six-component force-moment sensor to which the humerus was attached. The testing protocol includes measurement of glenohumeral translation in the anterior, anterior-inferior and inferior directions at 0°, 30° and 60° of glenohumeral abduction, respectively, with a passive humerus load of 30 N in the testing direction. The maximum possible external rotation was measured at each abduction angle applying a moment of 1 Nm. Each specimen was measured in a physiologic state, as well as after Bankart lesion with an anterior bone defect of 15–20% of the glenoid, after arthroscopic subscapularis augmentation and after Bankart repair.

Findings: The arthroscopic subscapularis augmentation decreased the anterior and anterior-inferior translation. The Bankart repair did not restore the mechanical stability compared to the physiologic shoulder group. External rotation was decreased after arthroscopic subscapularis augmentation compared to the physiologic state, however, the limitation of external rotation was decreased at 60° abduction.

Interpretation: The arthroscopic subscapularis augmentation investigated herein was observed to restore shoulder stability in an experimental model.

© 2016 Elsevier Ltd. All rights reserved.

1. Introduction

Shoulder dislocation is a common injury in young and active patients (Owens et al., 2007) with an incidence rate of 1.7%. Without surgical treatment, the recurrence rate in young patients is unacceptably high (70.3%) (Gigis et al., 2014). However, after arthroscopic Bankart repair, a recurrence rate of 13.1% was still reported in young patients (Gigis et al., 2014) and, in a systematic review, an odds ratio of 12.71 (Longo et al., 2014) was measured. After more than one dislocation, different pathologies are involved in the problem of instability: bone loss of the glenoid (Saito et al., 2005), Hill-Sachs defect with potential engaging at the glenoid rim (Purchase et al., 2008), capsular insufficiency

(stretched capsule (Osmond-Clarke, 1948)) and elongation of the subscapularis tendon (Symeonides, 1972).

In the early 20th Century, Putti and Platt inaugurated (independently from one another in Italy and England) an open shoulder soft tissue stabilization procedure, using the subscapularis tendon. This procedure is performed as follows: release of the subscapularis tendon at 2.5 cm medial of the insertion at the lesser tuberosity, open the capsule and suture the medial border of the lateral stump to the capsule tissue, and at least suture the lateral border of the medial subscapularis tendon laterally. Osmond-Clark was the first who described the procedure (Osmond-Clarke, 1948). After the first encouraging results, late complications such as osteoarthritis and the limitation of external rotation were reported (Ahmad et al., 2005; Hawkins and Angelo, 1990). Different modifications of the Putti-Platt procedure were described in the following years (Symeonides, 1989). Bristow (Helfet, 1958) and Latarjet (1954) both described a non-anatomical procedure using the conjoined tendon (biceps and coracobrachialis tendon) with the attached coracoid. The difference was that Bristow used just the conjoined tendon with the

* Corresponding author at: Department of Traumatology and Reconstructive Surgery, Eberhard Karls University Tübingen, BG Trauma Center Tübingen, Schnarrenbergstr. 95, D-72076 Tübingen, Germany.

E-mail address: schroeter.steffen@t-online.de (S. Schröter).

tip of the coracoid and Latarjet used the attached bone block, passed the conjoined tendon through the subscapularis tendon, and fixed the bone block at the glenoid. This procedure solves the problem of the bone loss, capsular insufficiency and elongation of the subscapularis tendon (i.e. the triple effect). With the development of arthroscopic surgery and instruments, it has become more popular to perform this procedure arthroscopically. However, although high complication rates after the early Bristow procedures (Artz and Huffer, 1972; Fee et al., 1978; Iftikhar et al., 1984) as well as after the arthroscopic Bristow-Latarjet procedure (Griesser et al., 2013a, 2013b) were reported, their popularity increased, especially in France and in German-speaking countries. Moreover, the indication depends on the surgical tradition of the countries. The pathological problems of a stretched capsule and elongation of the subscapularis tendon are the main problems related to the recurrence of instability (Symeonides, 1972). Recently, biomechanical studies have reported that the sling effect of the subscapularis is the main effect of stabilization after the Latarjet procedure (Giles et al., 2013; Wellmann et al., 2009; Wellmann et al., 2012).

Therefore, Johnson (1986) reported an arthroscopic technique using the subscapularis tendon to address the capsule-labral insufficiency. This procedure has been developed using the effect of the subscapularis tendon to stabilize the shoulder, thus avoiding a high complication rate, especially the major complication of nerve palsy. However, this procedure was abandoned due to complications related to the metal staple used for tendon fixation to the glenoid edge.

Recently, four techniques have been described in which the subscapularis tendon was used to treat anterior capsulolabral insufficiency. The first technique, described by Denard et al. (2011), consisted of a subscapularis flap used to augment the Bankart repair, whereas the second technique, described by Chaudhury et al. (2014), consisted of a complete tenodesis of the tendon and its advancement and fixation to the medial border of the glenoid neck using a large number of anchors. The third technique described by Blasiak et al. (2016) used a split of the subscapularis tendon which was detached from the distal part and fixed at the anterior glenoid rim. Fourth technique was presented by Klungsoyr et al. (2015) in a cadaver study. The “sling effect” was used to stabilize the shoulder using a hamstring graft and enhancing the anterior rim of the glenoid with the same graft.

Based on the procedure of Johnson (1986) a new arthroscopic technique consisting of an upper third subscapularis tenodesis at the anterior border of the glenoid rim combined with a Bankart repair, especially of the anterior-inferior capsule (Maiotti and Massoni, 2013) was developed. This technique was named *arthroscopic subscapularis augmentation* (A.S.A.). The recently published clinical results with a follow-up of 31.5 months are encouraging (Maiotti et al., 2015). They found in a group of patients with anterior shoulder instability and an anterior glenoid bone loss of <25% good clinical results (Rowe score 94.1 SD 6.7) with a low recurrence rate of 3.3%. No limitation in internal rotation as well as in abduction and flexion were found. In contrast there were a difference of 6° in external rotation with the arm at the side of the trunk and 3° with the arm at 90° of abduction, to the contralateral side. This limitation is not influencing sports activity and the patients did not complain on limitation.

However, there is still a discussion over whether the procedure stabilizes the shoulder and limits external rotation. Therefore, biomechanical testing is required to examine (i) the stabilization effect of the A.S.A., and (ii) the motion in the glenohumeral joint. The purpose of the presented study was to examine the biomechanical effect of this new augmentation technique on glenohumeral joint motion and stability. It was hypothesized that the translation after the A.S.A. is comparable to an injury-free shoulder, and the limitation of external rotation is <10° in 60° abduction.

2. Materials and methods

Eight human cadaver shoulder specimens were tested in a robot based shoulder simulator. Translational stability and range of motion

of each specimen was tested in four different configurations: physiologic, Bankart lesion with bony defect, A.S.A. and Bankart repair.

2.1. Preparation of the specimens

After receiving local IRB approval (No. 2640-2015), eight shoulders (4 male, 4 female) without evidence of rotator cuff tear and shoulder injury in their medical history were investigated (four right and four left shoulders). The mean donor age was 47.7 SD 8.7 years. The specimens were fresh-frozen and stored at a temperature of -20°C until experiments. The specimens were thawed at room temperature for 24 h prior to testing. The medial scapula margin was dissected through the soft tissue, without dissecting parts of the musculus subscapularis. The scapula was then potted and fixed in a customised box by use of a cold curing three-component casting resin (Rencast FC52/53 Isocyanate, FC53 Polyol, DT982, Gös&Pffaff GmbH, Karlskron/Braulach, Germany).

Afterwards, a K-wire was positioned parallel to the epicondyle axis 15 cm distal of the edge of the acromion. The humerus was then resected approximately 20 cm distal from the acromion edge, and potted in a brass cylinder using the same casting resin. The scapula of the specimen was mounted rigidly at the testing apparatus using thread rods. Neutral rotation of the glenohumeral joint was defined as a 10° internal rotation of the epicondyle axis (K-wire at the humerus) to the mounting tower (Fig. 1). The brass humeral cylinder was mounted to the robot using two threaded rods through an additional cylinder that was fixed on the wrist of the robot (Fig. 2). The humeral and global coordinate systems were defined as has been previously described (Hurschler et al., 2004). For testing, the head was centered in the glenoid. Antero-posterior and superior-inferior translations were measured by defining the location of geometric center of the humeral head to be zero at the starting point of each test. The starting point was re-established by the robot before each test condition.

2.2. Test setup and protocol

The setup consists of a force-guided industrial robot (KR15/1, Kuka GmbH, Augsburg, Germany) fitted with a six-component force-moment sensor (FMS) (KMS60, IpeA GmbH, Berlin, Germany) to which the humerus was attached, as described above. The robot applies force and moment-controlled motion and loads to the glenohumeral joint. The robot is capable of applying controlled loading by interpreting the load and moment data provided by the FMS (closed-loop control). The robot/FMS system enables measurement of motion with a resolution of 0.1 mm and measurement of joint loading with a resolution of <0.3 N force. During translation a normal force of 20 N were applied by the rotator cuff (Poppen and Walker, 1978; Veeger et al., 1991). Therefore, the humeral head was centered in the glenoid cavity at each abduction and rotation angle by an axial compressive load of 30 N. The testing protocol includes measurement of glenohumeral translation in anterior, anterior-inferior and inferior direction at 0° , 30° and 60° abduction in the frontal plane, respectively, with a humerus load of 30 N in the testing direction. Because the scapula was fixed, 60° glenohumeral abduction was assumed to correspond to 90° abduction of the arm (Debski et al., 1999). The protocol was repeated in neutral (0° external rotation) as well as 20° of external rotation.

During testing, the glenohumeral joint was free to translate in the mediolateral, superoinferior and anteroposterior direction, while rotation, flexion and elevation were held constant. In a further testing step, a torsional moment of 1 Nm was applied to the humerus to measure the range of motion (RoM) in external rotation (Fig. 3).

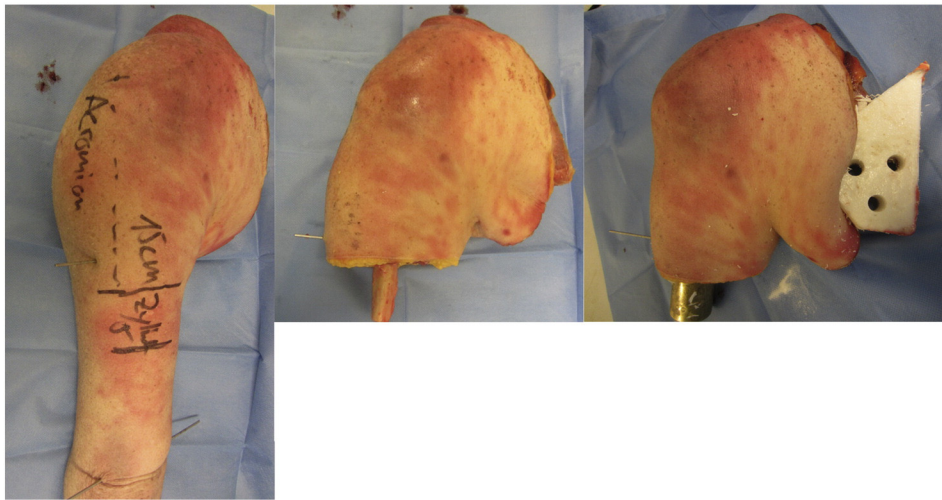


Fig. 1. Shoulder specimen. A: Measurement of the resection of the humerus with orientation at the acromion. Two k-wires are positioned parallel to each other in the epicondyle axis. B: After resection of the humerus. C: After fixation of the scapula and humerus.

2.3. Arthroscopic procedures

2.3.1. Bankart lesion

For the arthroscopic procedure, the shoulder was mounted with the scapula in the lateral decubitus position, and the humerus was fixed at 40° abduction and 15° flexion. A standard posterior portal (camera) and an accessory anterior-superior, as well as an anterior-inferior portal entering just superior the subscapularis tendon, were established, and a cannula was also positioned. The labral and capsule soft tissue was detached using a Bankart knife from 1 o'clock to 6 o'clock (right side) or 11 o'clock to 6 o'clock (left side) relative to the glenoid. Afterwards, the diameter of the glenoid was estimated with a calibrated hook. The

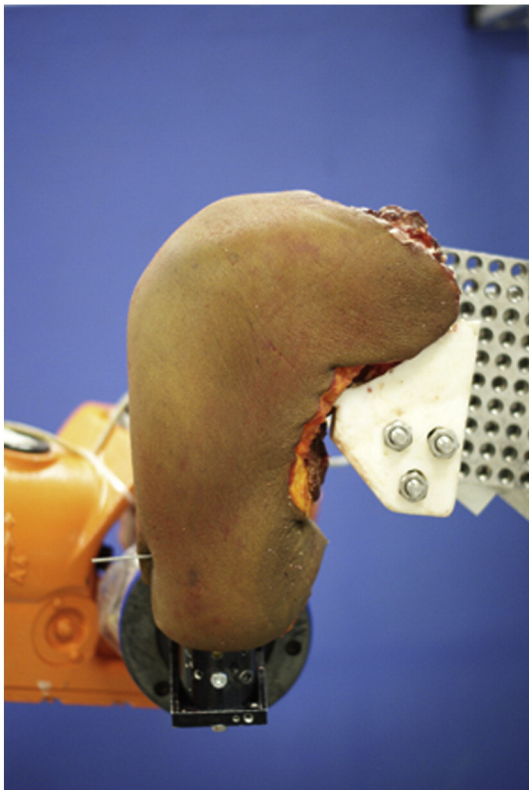


Fig. 2. The specimen is mounted at the robot.

15–20% crescent shaped glenoid defect was created at the anterior aspect of the glenoid rim according the results of Saito et al. (Saito et al., 2005) at the 3 o'clock position relative to the glenoid using a round burr of 5 mm (Arthrex, Naples, FL, USA). An estimation of the finally created defect was made with the camera in the antero-superior position (Fig. 4).

2.3.2. Arthroscopic subscapularis augmentation

The arthroscopic subscapularis augmentation combined with Bankart repair (A.S.A.) was then performed. The anterior-inferior capsulolabral complex was first reattached using a suture lasso to pass the 1.5 mm low profile LabralTape (Arthrex, Naples, FL, USA) through the tissue which was then fixed with a 2.9 × 15.5 mm Bio-PushLock (Arthrex, Naples, FL, USA) at the 5 o'clock position (w/r to a right-hand shoulder). Afterwards, a penetrator was used to pass the upper third of the subscapularis tendon 5 mm under its superior border in neutral rotation of the humerus; a 1.5 mm Labral Tape was used to shackle the tendon. The upper third of the subscapularis tendon was attached with an additional 3.5 × 19.5 mm Bio-PushLock Anchor to the 3 o'clock position in the right shoulder, and to the 9 o'clock position in the left shoulder (Fig. 5).

2.3.3. Bankart repair

The Labral Tape of the subscapularis tendon (from the A.S.A. procedure) was cut and a Bankart repair with labral fixation at the 3 o'clock position in the right, and at 9 o'clock position in the left shoulder, using Labral Tape and 2.9 × 15.5 mm Bio-Push Lock were performed (Fig. 6).

2.4. Statistical analysis

For statistical data analysis of the translation and rotation for the physiologic group, Bankart Lesion, the A.S.A. procedure and Bankart repair, Mann-Whitney-U tests were carried out. A significance level of $\alpha = 0.05$ was applied. Prism 6 for Mac OS X (GraphPad Software, La Jolla, CA, USA) was used for the statistical analysis. A sample size of eight specimens was calculated for an effect size of 10° difference of rotation to reach a power of 0.8.

3. Results

One specimen was excluded from the A.S.A. group due to repeated anchor loosening. Furthermore, immediate dislocation of the joint at the beginning of the translation testing prevented quantification of

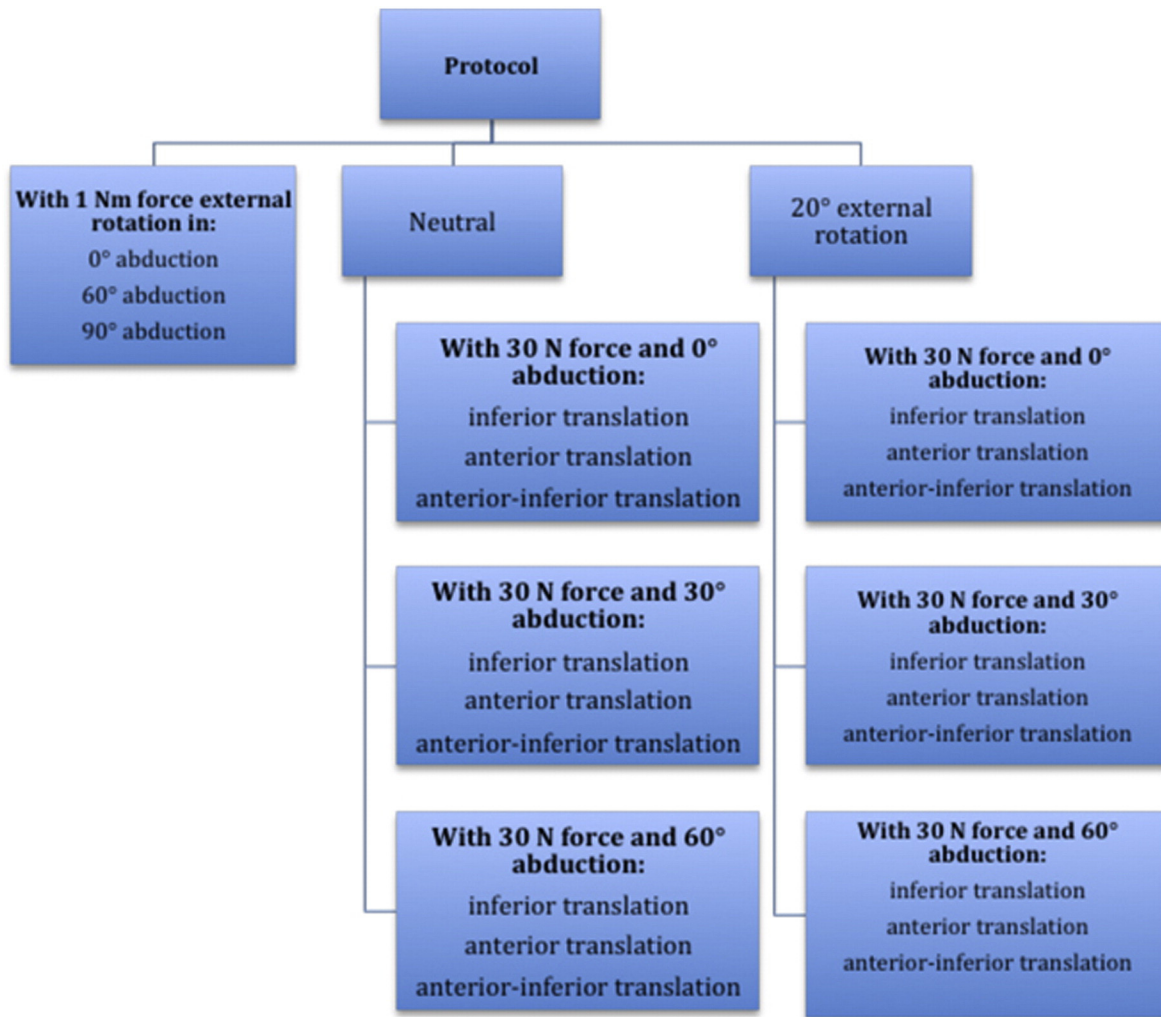


Fig. 3. Protocol of the biomechanical testing.

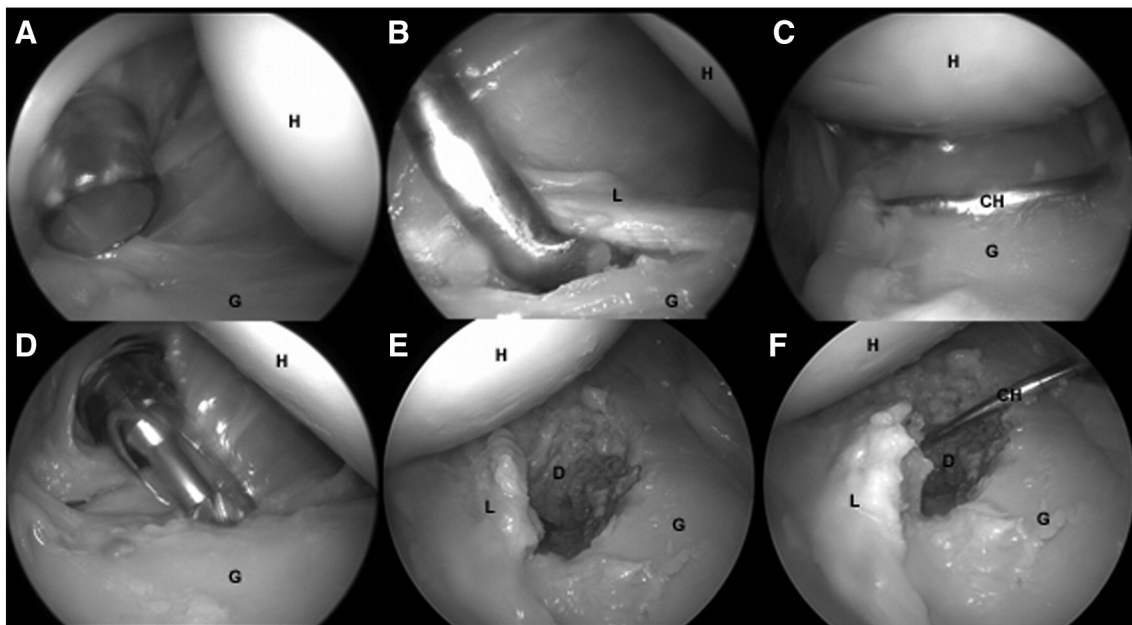


Fig. 4. Right shoulder in lateral decubitus position. A: View from posterior portal. B: Detachment of the capsule-labral complex with the Bankart knife. C: View from the anterior-superior portal. Measurement of the main distance of the glenoid. D: Resection of the bone at the anterior-inferior border at the glenoid. E: Result after resection of the bone. F: Measurement of the defect with the calibre hook. H: Humeral head, G: Glenoid, L: Labrum.

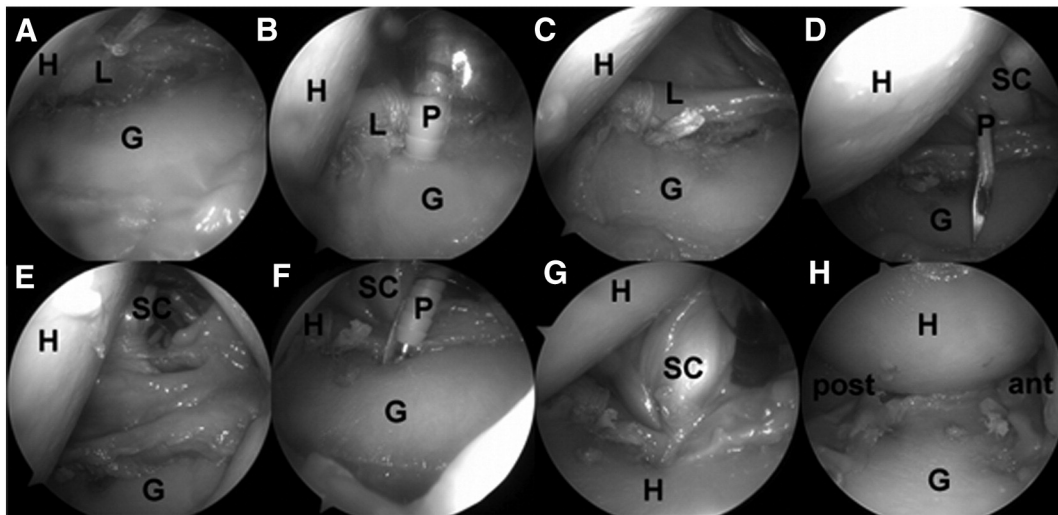


Fig. 5. Left shoulder. A.S.A. procedure in lateral decubitus position. A: View from the posterior portal. Anterior-inferior labrum is fixed with the LabralTape. B: Fixation of the labrum with a PushLock anchor. C: Fixed labrum. D: Penetration of the subscapularis tendon with a penetrator loaded with LabralTape. E: Subscapularis tendon is looped. F: Subscapularis tendon is fixed with the PushLock anchor at the glenoid at 9 o'clock position. G: Result of the ASA. H: View from the anterior-superior portal. Humeral head is centralized in the glenoid. H: Humeral head, G: Glenoid, L: Labrum, P: Penetrator, SC: Subscapularis tendon.

joint stability in some specimens. Depending on arm position, dislocation occurred in two to three of these specimens in the lesion group at 30° and 60° of abduction, and a further specimen dislocated in the Bankart group in all directions at 30° and 60° of abduction and 20° of external rotation. Furthermore, in the A.S.A. group limited range of motion prevented testing in some positions. Thus, in one specimen 0° of abduction could not be attained, external rotation of 20° was only possible in one specimen at 0° abduction, and all but two at 30° of abduction.

3.1. Translation testing

The creation of a Bankart lesion with additional bone defect resulted in significantly increased translations in the following arm positions compared to the physiologic group: inferior direction translations

significantly increased by 3.4 mm (SD 3.2 mm, $p = 0.01$) and 12.6 mm (SD 4 mm, $p < 0.005$) in 0° external rotation, and at 0° and 30° of abduction respectively (Fig. 7). Furthermore, in 20° external rotation and 30° abduction inferior translation increased by 12.1 mm (SD 9.8 mm, $p = 0.006$).

Antero-inferior translation significantly increased by 5.4 mm (SD 5.0 mm, $p = 0.015$) and 12.9 mm (SD 4.2 mm, $p < 0.005$) in 0° external rotation at 0° and 30° of abduction respectively (Fig. 8). Additionally, in 20° external rotation at 0° and 30° of abduction, antero-inferior translation increased by 8.5 mm (SD 4.7 mm, $p < 0.005$) and 11.1 mm (SD 7.8 mm, $p < 0.005$).

Comparing the Bankart repair with the lesion group, the following significant decrease in translation could be observed: Anterior-inferior and inferior translation significantly decrease by 7.0 mm (SD 7 mm,

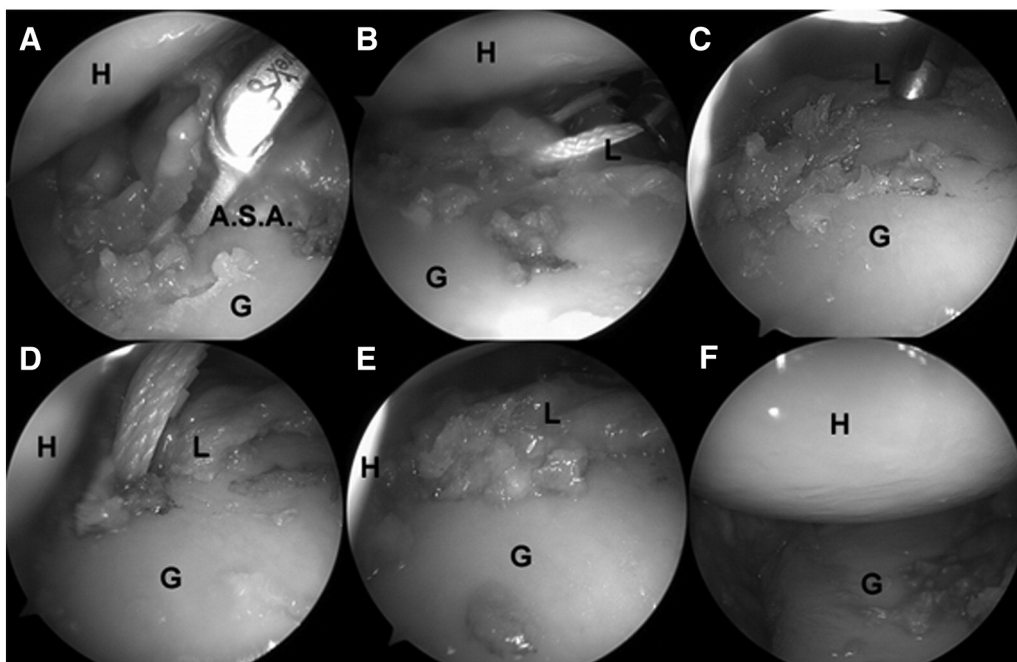


Fig. 6. Left shoulder. Bankart repair in lateral decubitus position. A: Cutting the A.S.A. B: Labrum is looped. C: Drilling for the PushLock. D: After fixation with the PushLock. E: Result of the fixed labrum, F: View from the anterior-superior portal. Humeral head is centralized in the glenoid. H: Humeral head, G: Glenoid, L: Labrum.

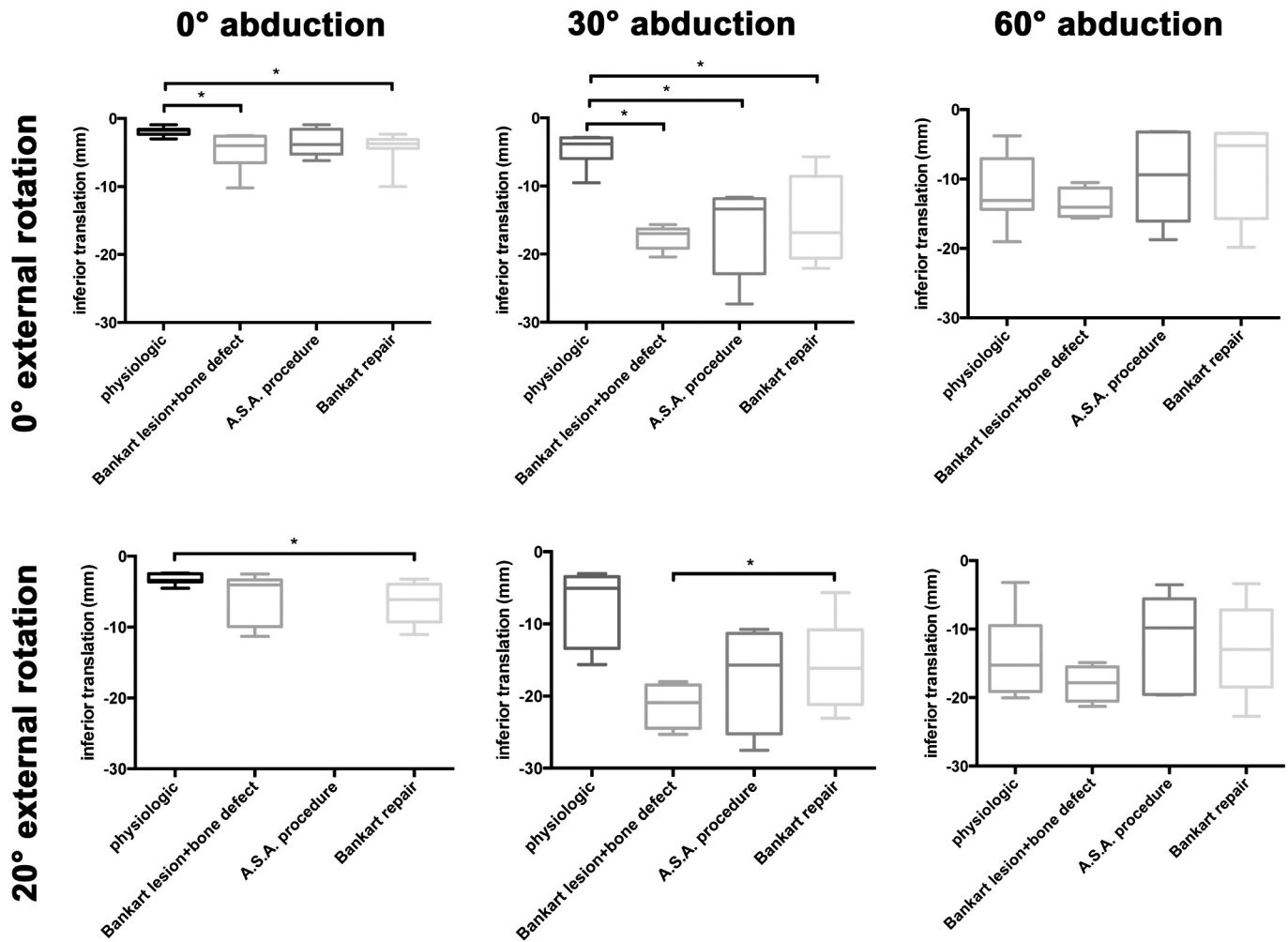


Fig. 7. Inferior translation of the glenohumeral joint. Measurements with the robot.

$p = 0.03$) and by 4.2 mm (SD 3.8 mm, $p < 0.05$) in 20° external rotation at 30° of abduction (Fig. 8).

Comparing the A.S.A. repair to the lesion group following significant decrease in translation could be observed: In anterior direction significantly decreased by 5.9 mm (SD 7.5 mm, $p = 0.035$) and 6.1 mm (SD 1.9 mm, $p = 0.01$) in 0° external rotation at 30° and 60° of abduction (Fig. 9). Additionally, in 20° external rotation at 60° of abduction, anterior translation was significantly decreased by 10.1 mm (SD 5.3 mm, $p = 0.035$). Furthermore, anterior-inferior translation was significantly decreased by 8.4 mm (SD 7.8 mm, $p = 0.01$) in 20° external rotation at 60° of abduction.

Translations of the A.S.A. group compared to the physiologic group were not significantly different in any direction and testing position with the exception of one case: The A.S.A. repair showed significantly decreased inferior translation in 0° external rotation ant 30° of abduction ($p = 0.002$, Fig. 7).

Comparing the Bankart repair group with the physiologic group, significant increase in inferior translation could be found in 0° external rotation at 0° ($p = 0.015$) and 30° ($p < 0.005$) of abduction and in 20° external rotation at 0° ($p = 0.05$) of abduction. Furthermore, significant differences were found for the anterior-inferior direction at 0° external rotation and 0° ($p = 0.038$) of abduction (Fig. 8).

3.2. Maximum rotation

External rotation of the glenohumeral joint was not influenced by the Bankart lesion, while the A.S.A. procedure resulted in significantly

lowered maximum external rotation. External rotation in the physiologic condition was 56.6° (SD 20.3°), 91.3° (SD 20.9°) and 100.0° (SD 25.2°) in 0°, 30° and 60° abduction, respectively. The maximum rotation of the A.S.A. group compared to the physiologic group was significantly decreased by 43.7° (SD 28.5°, $p = 0.01$) and 48.6° (SD 34.4, $p = 0.009$) in 0°, 30° of abduction, respectively ($p < 0.05$) (Fig. 10). The differences of maximum rotation after Bankart repair compared to the physiologic group were not significant (Fig. 10).

4. Discussion

The aim of this study was to investigate the stabilizing effect of the A.S.A. procedure on translation and rotation in the glenohumeral joint after Bankart lesion with additional bony defect. The effect of the A.S.A. procedure was compared to the Bankart repair. The results of the study show that the A.S.A. procedure has a stabilizing effect in abduction and external rotation with trade-offs regarding the maximum external rotation. The A.S.A. procedure prevents the joint from dislocations after Bankart lesion with additional bone defect. Joint translation values after A.S.A. procedure were not significantly different compared to the physiologic shoulder. Furthermore, the A.S.A. procedure significantly increased joint stability after Bankart lesion in anterior and anterior-inferior direction with the arm in abduction and external rotation. The A.S.A. results in a limitation of external rotation in 0° and 30° of abduction. The limitation of external rotation decreases in 60° abduction. Indeed, the hypothesis that the limitation of external rotation is $<10^\circ$ could not be confirmed.

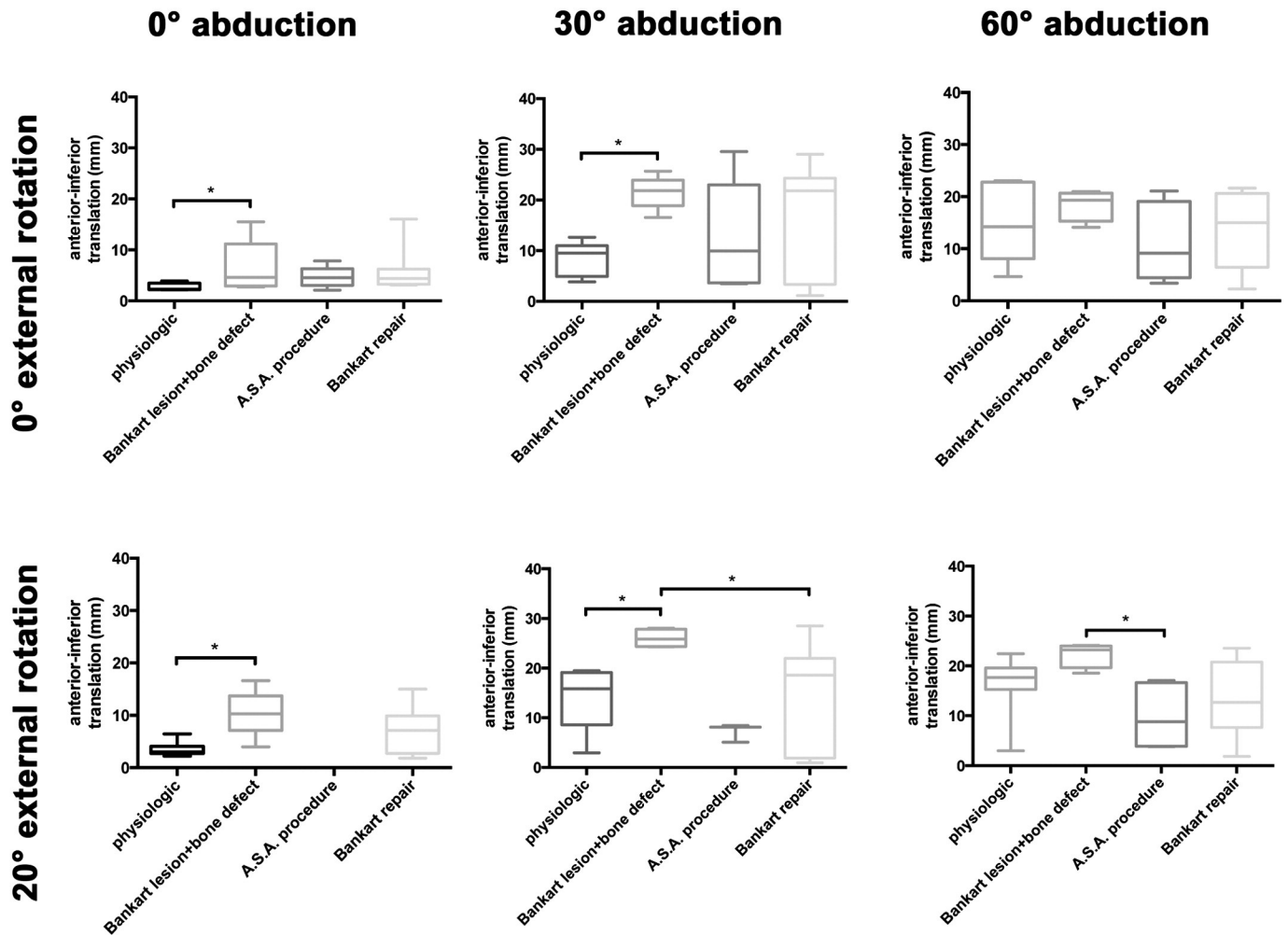


Fig. 8. Anterior-inferior translation of the glenohumeral joint. Measurements with the robot.

After Bankart lesion combined with a bone defect of 15–20%, translations with a load of 30 N significantly increased in a comparable manner to previous biomechanical studies (Kephart et al., 2014; Wellmann et al., 2012).

Bankart repair significantly decreased translations in single directions but was not able to stabilize the glenohumeral joint after Bankart lesion with additional bone defect in one specimen. Furthermore, the translation in specific arm positions was significantly increased in anterior-inferior and inferior direction compared to the physiologic group. These observations confirm the results of Yamamoto et al. (2009) and Burkhart and De Beer (2000). Yamamoto et al. (2009) found a decreased anterior stability with a bone defect with equal or >20% of the glenoid; Burkhart and De Beer (2000) highlighted the problem of recurrence after soft tissue procedure in the case of a bone defect. They found a rate of 67% recurrence if the bone defect was >20%.

The theory of the sling effect after the Bristow procedure could be helpful to understand the biomechanical stabilization effect of the A.S.A. The Bristow procedure pushes the lower third of the subscapularis tendon to the glenoid, which results in a posterior translation of the humeral head in relation to the glenoid (Kephart et al., 2014). Wellmann et al. (2012) analyzed the different stabilization aspects of the Latarjet procedure. They found increased anterior translation after cutting the conjoined tendon (group A) and cutting the subscapularis tendon (group B) after the Latarjet procedure. They summarized that an intact subscapularis tendon is a precondition to the success of the Latarjet procedure. Giles et al. (2013) analyzed specifically the theory of the sling effect of the Latarjet procedure. The specimens

were tested after the Latarjet procedure with and without load to the conjoined tendon. They found, that the loaded conjoined tendon prevented dislocation in all specimens. Whereas the unloaded conjoined tendon stabilized the shoulder in just 75% of the specimens. Interestingly the limitation of external rotation in 90° abduction was in the loaded group 29.0° (SD 6.2°) compared to the unloaded group. In 0° abduction no difference between the loaded and unloaded conjoined tendon was found. The explanation of this converse finding compared to the A.S.A. with less limitation in abduction compared to adduction could be an opposite sling effect. The Latarjet procedure uses the lower third of the subscapularis and the A.S.A. technique the upper third. These findings are important to understand the problem of shoulder instability with recurrent dislocations, and to outline the key role of the subscapularis tendon. There is still much debate regarding whether bone reconstruction in the case of a bone defect is necessary or not. In particular, two recently published biomechanical investigations support the opinion that the subscapularis tendon is the key to the solution. Kephart et al. (2014) investigated the Bristow procedure with and without the bone at the tip of the conjoined tendons, and found no differences in the stabilizing effect. Both created a bone defect size of 20%. In this study, an anatomical technique was used to increase the stability in cases of bone defects. The tenodesis of the subscapularis was able to reduce the translation.

It was not surprising that the tenodesis of the upper third of the subscapularis tendon results in a limitation of external rotation. However, the amount of limitation was unexpectedly high. To have less of a limitation of rotation, it is important to fix the upper third of the

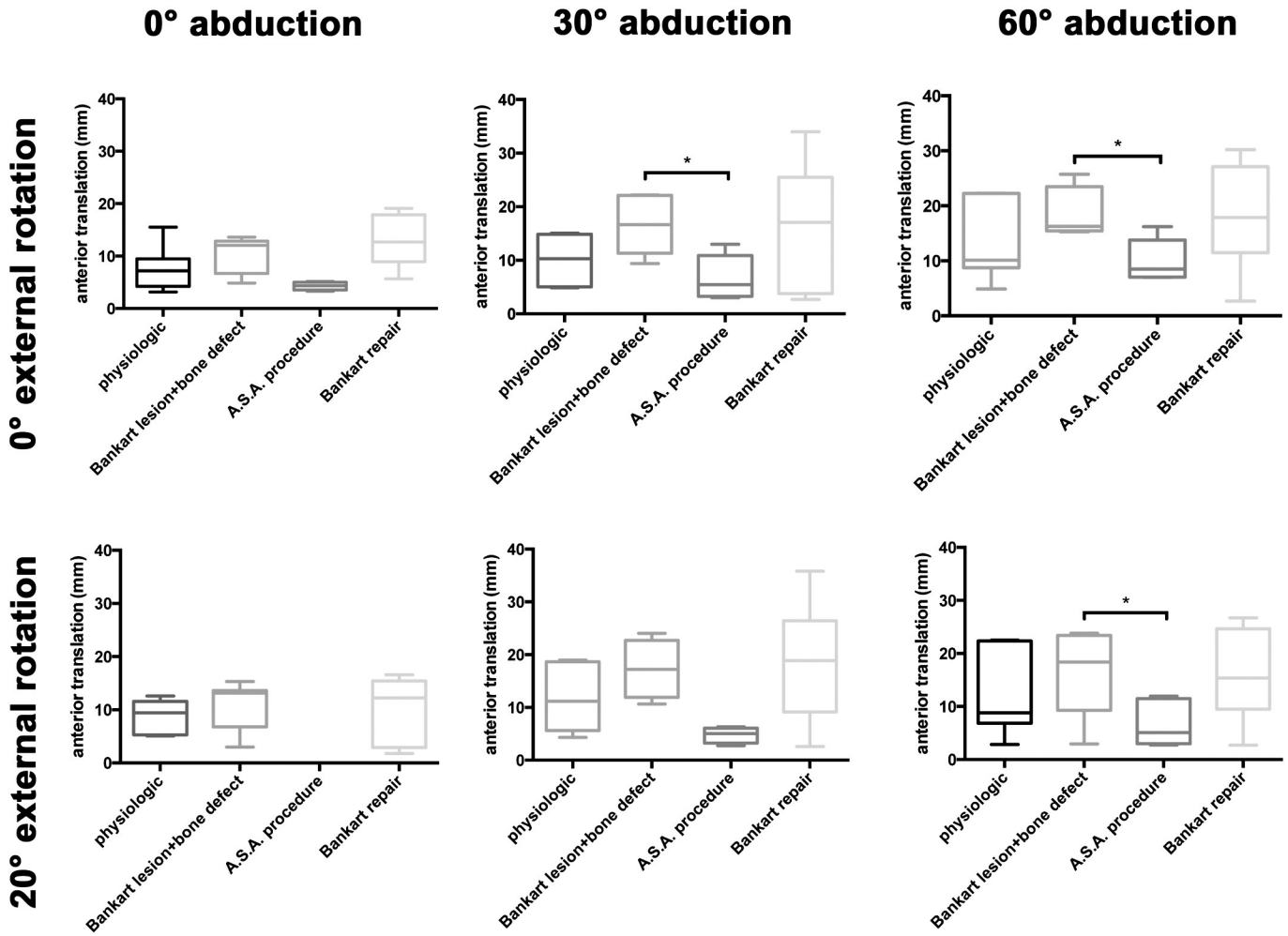


Fig. 9. Anterior translation of the glenohumeral joint. Measurements with the robot.

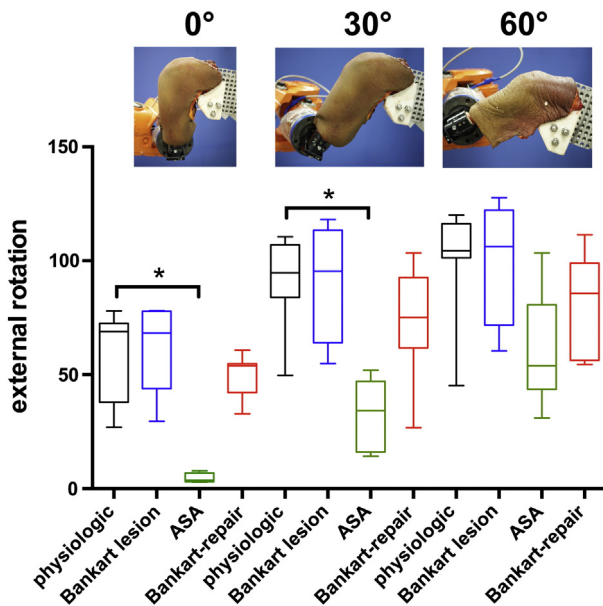


Fig. 10. Maximum external rotation of the glenohumeral joint. Measurements with the robot.

subscapularis tendon in a neutral position of the forearm. During the arthroscopic procedure, the assistant took care to obtain the correct rotation. The orientation was possible because of the k-wire in the humerus shaft parallel to the epicondyle axis. Therefore, rotation of the arm was unlikely to be the reason for the observed limitation. However, the clinical experience after the A.S.A. procedure are different concerning the limitation of external rotation (Maiotti et al., 2015). The limitation of external rotation was in 0° of abduction 6° and in 90° of abduction 3° after 31.5 months follow-up. A possible explanation of the different finding of the limitation of external rotation after the A.S.A. procedure in biomechanical testing comparing the clinical results could be the elongation of the tendon of the subscapularis (Symeonides, 1972). Furthermore, Tuoheti et al. (2005) observed a thinning of the subscapularis tendon in MRI after recurrent shoulder dislocations and assumed that it was the result of elongation of the tendon.

The results obtained in this study represent an immediate postoperatively state regarding the length of the subscapularis tendon. It is therefore still unknown how these results would change over time in clinical circumstances in which human tissue has the ability to physiologically relax and lengthen. It was not possible to reproduce in the specimens the anterior tissue lengthening due to the recurrent dislocations. This fact means that an in vivo elongated subscapularis tendon is used for tenodesis, and in this study, a tendon with normal length.

The finding of less limitation of external rotation in abduction than in adduction after a procedure using the subscapularis tendon for shoulder stabilization confirms, the findings of Collins et al. (1986). They

reported a loss of external rotation of 20° after the Putti-Platt procedure combined with the Bankart procedure; however, Hovelius et al. (1979) reported a loss of 6° after the Putti-Platt procedure. The difference between these studies after the Putti Platt procedure is the position of the arm for the measurement of the rotation. Hovelius et al. (1979) measured it at 90° abduction; Collins et al. at 0° abduction. This result could be explained by the different distances between the attachment of the subscapularis tendon at the humerus, and the tenodesis at the glenoid at 0° abduction vs. 60° abduction.

4.1. Limitations

Our study has some limitations. First of all, this technical setup only allows for analyses of the glenohumeral joint motion. The scapula was fixed in the test rig and therefore scapulothoracic motion could not be simulated. Furthermore, a randomized testing of the different groups was not possible and the repeated testing could have affected the stiffness of the soft tissue and thus the differences between the groups could have been influenced. In the group after bone defects and in the group after Bankart repair shoulder dislocations could be observed some cases and needed to be excluded from the analyses. Therefore, less data for statistical analysis were available and their significance could not be measured. Nevertheless, the differences, which could be observed, are valuable.

5. Conclusions

We found that the A.S.A. procedure decreases the anterior and anterior-inferior translation after Bankart lesion with additional bone defect and prevents shoulder dislocation in the biomechanical cadaver study. External rotation is limited in adduction, and this limitation decreases in abduction.

Appendix A. Supplementary data

Supplementary data to this article can be found online at <http://dx.doi.org/10.1016/j.clinbiomech.2016.08.012>.

References

- Ahmad, C.S., Wang, V.M., Sugalski, M.T., Levine, W.N., Bigliani, L.U., 2005. Biomechanics of shoulder capsulorrhaphy procedures. *Journal of shoulder and elbow surgery/American Shoulder and Elbow Surgeons ... [et al.]* 14, 12S–18S.
- Artz, T., Huffer, J.M., 1972. A major complication of the modified Bristow procedure for recurrent dislocation of the shoulder. A case report. *J. Bone Joint Surg.* 1293–1296 American volume 54.
- Blasiak, A., Brzoska, R., Mojiesz, M., Solecki, W., Grzegorzewski, A., 2016. Outcome Evaluation of Arthroscopic Treatment of the Anterior Shoulder Instability with Use of Extracapsular Stabilization by Using the BLS and “Remplissage” Techniques. *ESSKA, Barcelona*.
- Burkhart, S.S., De Beer, J.F., 2000. Traumatic glenohumeral bone defects and their relationship to failure of arthroscopic Bankart repairs: significance of the inverted-pear glenoid and the humeral engaging Hill-Sachs lesion. *Arthroscopy: the journal of arthroscopic & related surgery: official publication of the Arthroscopy Association of North America and the International Arthroscopy Association* 16, 677–694.
- Chaudhury, S., Delos, D., Dines, J.S., Altchek, D.W., Dodson, C.C., Newman, A.M., O'Brien, S.J., 2014. Arthroscopic subscapularis bankart technique as a salvage procedure for failed anterior shoulder stabilization. *HSS journal: the musculoskeletal journal of Hospital for Special Surgery* 10, 73–78.
- Collins, K.A., Capito, C., Cross, M., 1986. The use of the Putti-Platt procedure in the treatment of recurrent anterior dislocation. With special reference to the young athlete. *The American journal of sports medicine* 14, 380–382.
- Debski, R.E., Wong, E.K., Woo, S.L., Sakane, M., Fu, F.H., Warner, J.J., 1999. In situ force distribution in the glenohumeral joint capsule during anterior-posterior loading. *Journal of orthopaedic research: official publication of the Orthopaedic Research Society* 17, 769–776.
- Denard, P.J., Narbona, P., Ladermann, A., Burkhart, S.S., 2011. Bankart augmentation for capsulolabral deficiency using a split subscapularis tendon flap. *Arthroscopy: the journal of arthroscopic & related surgery: official publication of the Arthroscopy Association of North America and the International Arthroscopy Association* 27, 1135–1141.
- Fee, H.J., McAvoy, J.M., Dainko, E.A., 1978. Pseudoaneurysm of the axillary artery following a modified Bristow operation: report of a case and review. *J. Cardiovasc. Surg.* 19, 65–68.
- Gigis, I., Heikenfeld, R., Kapinas, A., Listringhaus, R., Godolias, G., 2014. Arthroscopic versus conservative treatment of first anterior dislocation of the shoulder in adolescents. *J. Pediatr. Orthop.* 34, 421–425.
- Giles, J.W., Boons, H.W., Elkinson, I., Faber, K.J., Ferreira, L.M., Johnson, J.A., Athwal, G.S., 2013. Does the dynamic sling effect of the Latarjet procedure improve shoulder stability? A biomechanical evaluation. *Journal of shoulder and elbow surgery/American Shoulder and Elbow Surgeons ... [et al.]* 22, 821–827.
- Griesser, M.J., Harris, J.D., McCoy, B.W., Hussain, W.M., Jones, M.H., Bishop, J.Y., Miniaci, A., 2013a. Complications and re-operations after Bristow-Latarjet shoulder stabilization: a systematic review. *Journal of shoulder and elbow surgery/American Shoulder and Elbow Surgeons ... [et al.]* 22, 286–292.
- Griesser, M.J., Harris, J.D., McCoy, B.W., Hussain, W.M., Jones, M.H., Bishop, J.Y., Miniaci, A., 2013b. Glenoid fracture after Bristow-Latarjet shoulder stabilization: a case report and review of the literature. *Journal of shoulder and elbow surgery/American Shoulder and Elbow Surgeons ... [et al.]* 22, e17–e20.
- Hawkins, R.J., Angelo, R.L., 1990. Glenohumeral osteoarthritis. A late complication of the putti-Platt repair. *J. Bone Joint Surg.* 1193–1197 American volume 72.
- Helfet, A.J., 1958. Coracoid transplantation for recurring dislocation of the shoulder. *J. Bone Joint Surg.* 198–202 British volume 40-B.
- Hovelius, L., Thorling, J., Fredin, H., 1979. Recurrent anterior dislocation of the shoulder. Results after the Bankart and Putti-Platt operations. *J. Bone Joint Surg. Am* 61 (4), 566–569.
- Hurschler, C., Wulker, N., Windhagen, H., Hellmers, N., Plumboff, P., 2004. Evaluation of the lag sign tests for external rotator function of the shoulder. *Journal of shoulder and elbow surgery/American Shoulder and Elbow Surgeons ... [et al.]* 13, 298–304.
- Iftikhar, T.B., Kaminski, R.S., Silva Jr., I., 1984. Neurovascular complications of the modified Bristow procedure. A case report. *J. Bone Joint Surg.* 951–952 American volume 66.
- Johnson, L.L., 1986. Principle and practice. In: Mosby (Ed.), *Arthroscopic surgery*, pp. 1420–1424 St. Louis.
- Kephart, C.J., Abdulian, M.H., McGarry, M.H., Tibone, J.E., Lee, T.Q., 2014. Biomechanical analysis of the modified Bristow procedure for anterior shoulder instability: is the bone block necessary? *Journal of shoulder and elbow surgery/American Shoulder and Elbow Surgeons ... [et al.]* 23, 1792–1799.
- Klungsoyr, P.J., Guldal, F., Vagstad, T., Klungsoyr, J.A., 2015. A new subscapular sling operation to stabilize the shoulder. A cadaver study. *J. Exp. Orthop* 2, 12.
- Latarjet, M., 1954. Treatment of recurrent dislocation of the shoulder. [A propos du traitement des luxations récidivantes de l'épaule.]. *Lyon chirurgical* 49, 994–997.
- Longo, U.G., Loppini, M., Rizzello, G., Ciuffreda, M., Maffulli, N., Denaro, V., 2014. Management of primary acute anterior shoulder dislocation: systematic review and quantitative synthesis of the literature. *Arthroscopy: the journal of arthroscopic & related surgery: official publication of the Arthroscopy Association of North America and the International Arthroscopy Association* 30, 506–522.
- Maiotti, M., Massoni, C., 2013. Arthroscopic augmentation with subscapularis tendon in anterior shoulder instability with capsulolabral deficiency. *Arthroscopy techniques* 2, e303–e310.
- Maiotti, M., Russo, R., Zanini, A., Schroter, S., Massoni, C., Bianchedi, D., 2015. Arthroscopic Bankart repair and subscapularis augmentation: an alternative technique treating anterior shoulder instability with bone loss. *Journal of shoulder and elbow surgery/American Shoulder and Elbow Surgeons ... [et al.]*.
- Osmond-Clarke, H., 1948. Habitual dislocation of the shoulder; the Putti-Platt operation. *J. Bone Joint Surg.* 19–25 British volume 30B.
- Owens, B.D., Duffey, M.L., Nelson, B.J., DeBerardino, T.M., Taylor, D.C., Mountcastle, S.B., 2007. The incidence and characteristics of shoulder instability at the United States Military Academy. *The American journal of sports medicine* 35, 1168–1173.
- Poppen, N.K., Walker, P.S., 1978. Forces at the glenohumeral joint in abduction. *Clin. Orthop. Relat. Res.* 165–170.
- Purchase, R.J., Wolf, E.M., Hobgood, E.R., Pollock, M.E., Smalley, C.C., 2008. Hill-Sachs “remplissage”: an arthroscopic solution for the engaging hill-sachs lesion. *Arthroscopy: the journal of arthroscopic & related surgery: official publication of the Arthroscopy Association of North America and the International Arthroscopy Association* 24, 723–726.
- Saito, H., Itoi, E., Sugaya, H., Minagawa, H., Yamamoto, N., Tuoheti, Y., 2005. Location of the glenoid defect in shoulders with recurrent anterior dislocation. *The American journal of sports medicine* 33, 889–893.
- Symeonides, P.P., 1972. The significance of the subscapularis muscle in the pathogenesis of recurrent anterior dislocation of the shoulder. *J. Bone Joint Surg.* 476–483 British volume 54.
- Symeonides, P.P., 1989. Reconsideration of the Putti-Platt procedure and its mode of action in recurrent traumatic anterior dislocation of the shoulder. *Clin. Orthop. Relat. Res.* 8–15.
- Tuoheti, Y., Itoi, E., Minagawa, H., Wakabayashi, I., Kobayashi, M., Okada, K., Shimada, Y., 2005. Quantitative assessment of thinning of the subscapularis tendon in recurrent anterior dislocation of the shoulder by use of magnetic resonance imaging. *Journal of shoulder and elbow surgery/American Shoulder and Elbow Surgeons ... [et al.]* 14, 11–15.
- Veeger, H.E., Van der Helm, F.C., Van der Woude, L.H., Pronk, G.M., Rozendal, R.H., 1991. Inertia and muscle contraction parameters for musculoskeletal modelling of the shoulder mechanism. *J. Biomech.* 24, 615–629.
- Wellmann, M., Petersen, W., Zantop, T., Herbolt, M., Kobbe, P., Raschke, M.J., Hurschler, C., 2009. Open shoulder repair of osseous glenoid defects: biomechanical effectiveness of the Latarjet procedure versus a contoured structural bone graft. *The American journal of sports medicine* 37, 87–94.
- Wellmann, M., de Ferrari, H., Smith, T., Petersen, W., Siebert, C.H., Agneskirchner, J.D., Hurschler, C., 2012. Biomechanical investigation of the stabilization principle of the Latarjet procedure. *Arch. Orthop. Trauma Surg.* 132, 377–386.
- Yamamoto, N., Itoi, E., Abe, H., Kikuchi, K., Seki, N., Minagawa, H., Tuoheti, Y., 2009. Effect of an anterior glenoid defect on anterior shoulder stability: a cadaveric study. *The American journal of sports medicine* 37, 949–954.